

## Occuli dextra proptosis in symptomatic hiperthyroidism with diffuse goitre in 45-year-old-woman: A case report with literature review

**Timotius<sup>1</sup>, Ananda Putra<sup>2</sup>, Johansen<sup>4</sup>, Pussuf Yayazucuh Titanic<sup>4</sup>, Diana Novitasari<sup>5\*</sup>**

<sup>1,3,4,5</sup>Medical Professional Program Faculty of Medicine Tarumanagara University, Jakarta

<sup>2</sup>Department of Internal Medicine KRMT Wongsonegoro General Hospital Semarang

### ABSTRACT

Hyperthyroid is refers to increased of thyroid synthesis hormon production by the thyroid gland that cause an excessive amount thyroid homrone circulate in the blood and eventually cause protrusion of unilateral or both eyes at the anterior out of the orbit due to an increased orbital content within the rigid bony orbit. We report the case of 45 -year-old woman with major complaints of blurred vision on her right eye. Blurred vision on this patient is without a red eye but have a tension on his eye that feel like going out. On local examination of the neck area, there was visible mass during inspection, and on palpation there mass in the neck area. On laboratory examination, TSHs levels were 0.085 uIU/mL, FT4 levels were 12.8 pmol/L, creatinine was 0.9 mg/dL, Calcium was 1.23 mmol/L, Natrium 134 mmol/L, Kalium 3.30 mmol/L. On Colli ultrasound, multiple lymphadenopathy were found on the right and left Colli measuring 1.65 cm x 0.6 cm in the right Colli and 2.10 cm x 0.35 cm in the left Colli and on Head CT-scan with contrast orbita centration, Brain edema and proptosis on occuli dextra were found. The patient underwent oral therapy using propylthiouracil and intravenous methylprednisolone therapy. Administered intravenous methylprednisolone pulse therapy show a significant decrease on grave ophthalmopathy severity.

**Keywords:** occuli dextra proptosis; symptomatic hyperthyroidism; diffuse goitre

## Occuli dextra proptosis pada hipertiroidisme simtomatik dengan gondok difus pada wanita berusia 45 tahun: Laporan kasus dengan tinjauan literatur

### ABSTRAK

Hipertiroid mengacu pada peningkatan produksi hormon sintesis tiroid oleh kelenjar tiroid yang menyebabkan jumlah homrone tiroid yang berlebihan beredar dalam darah dan akhirnya menyebabkan tonjolan mata unilateral atau kedua mata di anterior keluar dari orbit karena peningkatan kandungan orbital dalam orbit tulang kaku. Kami melaporkan kasus wanita berusia 45 tahun dengan keluhan utama penglihatan kabur di mata kanannya. Penglihatan kabur pada pasien ini adalah tanpa mata merah tetapi memiliki ketegangan pada matanya yang terasa seperti keluar. Pada pemeriksaan lokal daerah leher, ada massa yang terlihat selama inspeksi, dan pada palpasi ada massa di daerah leher. Pada pemeriksaan laboratorium, kadar TSHs 0,085 uIU/mL, kadar FT4 12,8 pmol/L, kreatinin 0,9 mg/dL, Kalsium 1,23 mmol/L, Natrium 134 mmol/L, Kalium 3,30 mmol/L. Pada USG Colli, ditemukan limfadenopati multipel pada Colli kanan dan kiri berukuran 1,65 cm x 0,6 cm pada Colli kanan dan ditemukan 2,10 cm x 0,35 cm pada Colli kiri dan pada CT-scan Kepala dengan konsentrasi orbita kontras, edema otak dan proptosis pada occuli dextra. Pasien menjalani terapi oral dengan menggunakan propylthiouracil dan terapi methylprednisolone intravena. Terapi pulsa methylprednisolone intravena yang diberikan menunjukkan penurunan yang signifikan pada keparahan ophthalmopati berat.

**Kata Kunci:** occuli dextra proptosis; hipertiroidisme simtomatik; gondok difus

Corresponding author: Dr. Diana Novitasari

Department of Internal Medicine KRMT Wongsonegoro General Hospital Semarang.

Email: budianainterna@gmail.com\*

## INTRODUCTION

Hyperthyroid is a disorder of the thyroid glands in which there is excessive secretion of thyroid from one or more thyroid glands and ultimately causes an increase TSHs on the bloodstream (De Leo et al., 2016). Graves' disease or hyperthyroidism, is one of the hormonal disorders caused by the overproduction of thyroid hormones by the thyroid gland. Common symptoms of hyperthyroidism include an increased heart rate, weight loss, tremors, and exophthalmos or proptosis. Proptosis is a condition in which a person's eye protrudes out of the eye socket. One of the complications that can occur in hyperthyroidism is oculi dextra proptosis. The cause of proptosis in hyperthyroidism is the enlargement and inflammation of tissues around the eye, resulting from the accumulation of connective tissue within the eye orbit (Sajjadi-Jazi et al., 2018).

Cases of proptosis in hyperthyroidism are a common clinical issue. However, it should be noted that not all hyperthyroidism patients experience proptosis. Moreover, there is limited literature addressing cases of oculi dextra proptosis in hyperthyroidism patients with diffuse goitre among 45-year-old women. Diffuse goitre is a condition in which the thyroid gland swells, leading to changes in neck morphology (Şahlı & Gündüz, 2017).

Numerous previous studies have explored the relationship between hyperthyroidism and proptosis. Nevertheless, most of these studies have focused on pathophysiological aspects rather than case presentations. Case studies similar to oculi dextra proptosis in 45-year-old women with hyperthyroidism and diffuse goitre are notably limited.

In most cases, primary hyperthyroid can be caused by parathyroid adenoma, MEN (multiple endocrine neoplasia) types 1 and 2, hyperparathyroidism-jaw tumor syndrome, and familial hyperparathyroidism. In rare cases, it can be caused by parathyroid carcinoma.

We report a case of primary hyperparathyroidism with a suspected hyperparathyroid adenoma with a PTH level of 455.8 pg/mL and a blood calcium level of 13.5 mg/dL.

Regarding cases of oculi dextra proptosis in patients with hyperthyroidism and diffuse goitre, there is inadequate information available in medical literature. Thus, this research aims to fill this knowledge gap and provide further insights into the characteristics, clinical presentation, and management of similar cases.

The primary objective of this study is to document and analyze a case of oculi dextra Proptosis in a 45-year-old woman with hyperthyroidism and diffuse goitre. This research also aims to understand the contributing factors to proptosis in such cases.

## RESEARCH METHOD

A 45-year-old woman came to the Endocrine, Metabolism and Diabetes clinic at RSUD K.R.M.T Wongsonegoro on Dec 12, 2022 with complaints blurred vision on her right eye. The blurred vision is accompanied with visibel mass. When watching, the patient feels blur and pain in her right eyes. The patient's pain has been felt since 1 years ago and has gotten worse in the last 2 months. The patient is also often get anxiety since last month and feels loss of appetite. The patient was not obese, had no history of trauma to the eye and neck. The patient denied pain in the epigastric area, nausea, vomiting, and fever. The patient had a history of hypertriglyceridemia but was controlled with daily anti-triglycerid drugs.

On physical examination, the patient was found to be active, compost mentis, GCS 15 (E4M6V5), blood pressure 130/95 mmHg, pulse 90 x/minute, temperature 37°C, respiratory rate 20x/minute, SpO2 99%. Local examination in the neck area, when the inspection was carried out there was visible mass with length and width 2.5 cm x 1 cm and on palpation there was soft lump with a size of 2.5 cm x 1 cm which is not painful and not reddened in the neck area. On eye examination, intraocular tension was found very high and there is bulging on her right eye.

On laboratory examination, TSHs levels were 0.085 uIU/mL, FT4 levels were 12.8 pmol/L, creatinine was 0.9 mg/dL, Calcium was 1.23 mmol/L, Natrium 134 mmol/L, Kalium 3.30 mmol/L. On ultrasound examination of Colli, multiple lymphadenopathy were found on the right and left Colli measuring 1.65 cm x 0.6 cm in the right Colli and 2.10 cm x 0.35 cm in the left Colli. On Head CT-scan with contrast orbita centration, Brain edema and proptosis on oculi dextra were found.

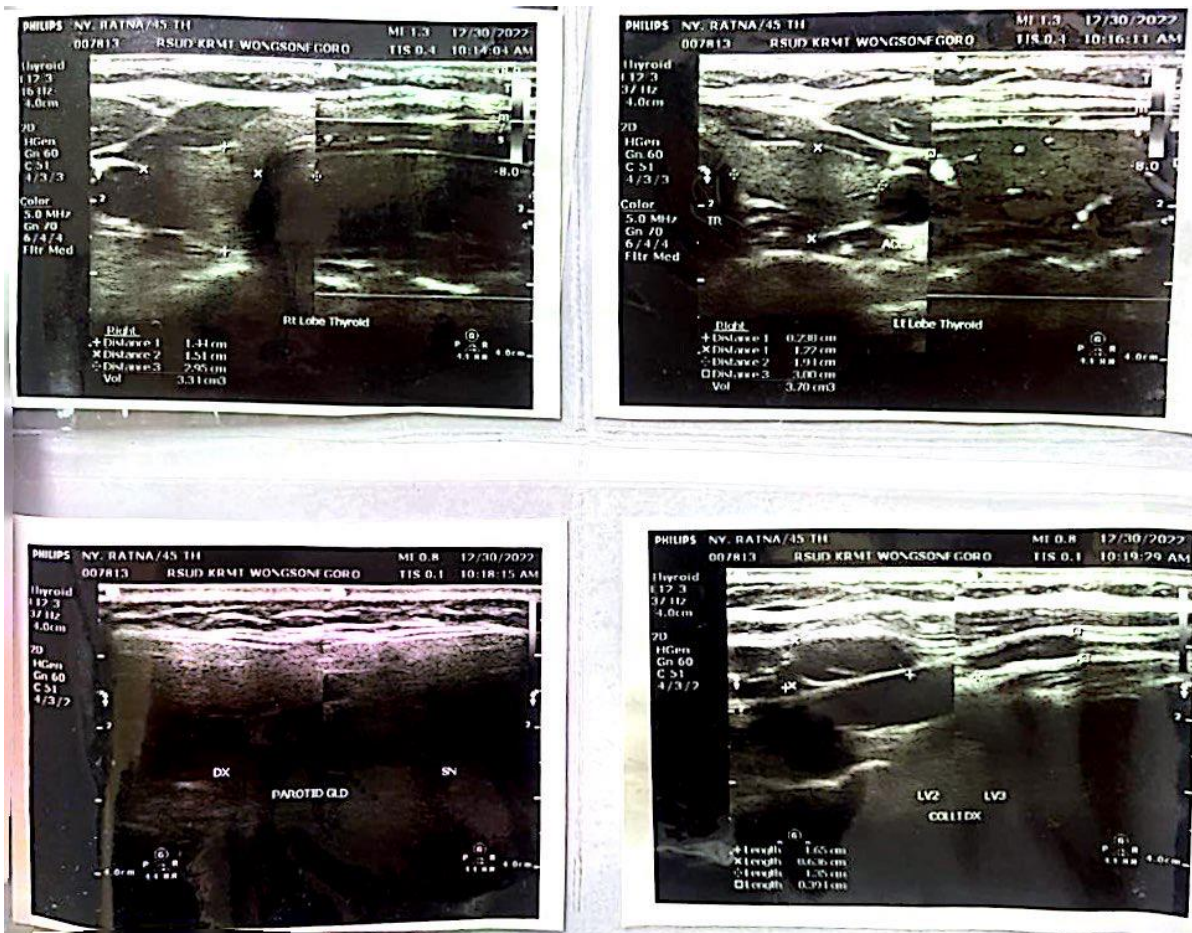


Figure 1: On colli ultrasound, multiple lymphadenopathy were found on the right and left Colli measuring 1.65 cm x 0.6 cm in the right Colli and 2.10 cm x 0.35 cm in the left colli.

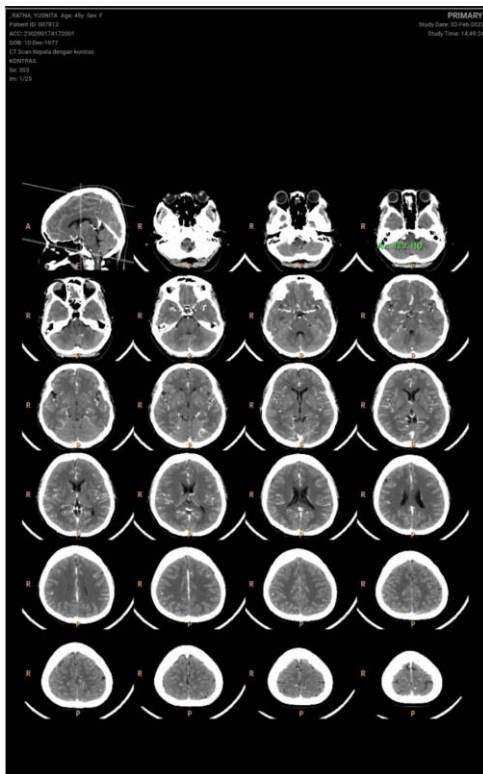


Figure 2: On CT-scan of head with contrast orbita centration, Brain edema and proptosis on occuli dextra were found.

## DISCUSSION

Hyperthyroid is a disorder that is caused by abnormal secretion of thyroid hormone in which there is excessive secretion of thyroid hormone from one or more thyroid glands and ultimately causes an increase in thyroid blood levels (De Leo et al., 2016).

According to the third National Health and Nutrition Examination Survey (NHANES III), the prevalence of hyperthyroidism in the US is 1.3% (0.5% overt and 0.7% subclinical). It is believed that roughly half of thyroid disease patients in the United States go undiagnosed. According to a meta-analysis of European research, the estimated prevalence and incidence of overt hyperthyroidism were 0.68% and 0.51/1000/year, respectively. Furthermore, most research found that females had a greater frequency and incidence rate (Sajjadi-Jazi et al., 2018). There is insufficient data on the epidemiology of hyperthyroidism in Indonesia.

While thyroid-associated ophthalmopathy (TAO) is 2.5 to 6-fold more frequent in women, males are more likely to develop severe ophthalmopathy. The condition usually manifests between the ages of 30 and 50, with the disease becoming more severe. Ophthalmopathy has been recorded in 25-50% of Graves' disease patients and 2% of Hashimoto's thyroiditis patients. Severe ophthalmopathy affects about 3-5% of these people. The majority of Graves' disease patients develop ophthalmopathy within 18 months after being diagnosed. However, the development of ophthalmopathy can occur up to 10 years before and up to 20 years after the commencement of thyroid disease (Şahlı & Gündüz, 2017).

Although the pathophysiology of TAO is unknown, it is believed to be an autoimmune condition. It has been proven that autoimmunity develops against thyroid gland and orbit antigens. Although some argue that TSH receptor is the common pathogenetic antigen, Salvi et al discovered a 64-kDa protein that is found in both the thyroid gland and the orbit. Recent research has found that the cardiac calsequestrin gene is upregulated in TAO patients, indicating that autoimmunity to calsequestrin may be a triggering element in the development of ophthalmopathy. Despite a tight relationship between ophthalmopathy and TSH receptor antibodies, antibodies against orbital fibroblast membrane antigen collagen XIII were discovered shortly after the announcement of autoimmunity against calsequestrin (Şahlı & Gündüz, 2017).

Exophthalmos is usually caused by an increase in orbital contents within the bony orbit, which causes the globe to move forward. The underlying reason determines the origin of the higher orbital content. Graves ophthalmopathy causes extraocular muscle growth and orbital adipose tissue expansion due to aberrant hyaluronic acid buildup and edema collection into the retro-orbital space (Huang et al., 2020). T cells detect thyroid-orbit antigens and infiltrate the orbit and extraocular muscle perimysium. This is aided by cytokine-stimulated circulating and local adhesion molecules. T-cell receptors on CD4+ T lymphocytes identify the same antigen when T cells infiltrate the orbit. Th lymphocytes release cytokines, which stimulate CD8+ lymphocytes and autoantibody-producing B cells, therefore strengthening the immune response. These cytokines promote fibroblasts' production and release of glycosaminoglycans (GAGs). GAGs cause periorbital edema, proptosis, and swelling of the extraocular muscles due to their water-attracting characteristics. Cytokine-stimulated fibroblast proliferation also contributes to orbital content expansion (Huang et al., 2020). Orbital fibroblasts contain preadipocytes, which transform into adipocytes in response to hormonal stimulus. These cells have been linked to an increase in the amount of retro-orbital fat tissue. Recent research has shown that thyroid autoantibodies and immune system genes play a significant role in predicting and defining the severity of ophthalmopathy before it develops. In the context of ophthalmopathy, anti-TPO antibody and anti-TG positive rates of 90% and 50%, respectively, have been recorded (Lin et al., 2017; Yang et al., 2019).

Excess thyroid hormone has a wide range of effects on many organ systems. Palpitations, weariness, tremor, anxiety, disrupted sleep, weight loss, heat intolerance, sweating, and polydipsia are all common symptoms. Tachycardia, trembling of the limbs, and weight loss are common physical symptoms. In Graves' disease, signs and symptoms include ophthalmopathy, thyroid dermopathy, and thyroid acropathy; in nodular goitre, globus feeling, dysphagia, or orthopnoea owing to oesophageal or tracheal compression; and in severe subacute thyroiditis, anterior neck discomfort (Wiersinga et al., 2006).

Ophthalmopathy, commonly known as Graves' orbitopathy, affects 25% of Graves' disease patients. Proptosis, periorbital oedema, and diplopia are the most common symptoms. Clinicians who lack competence in active or moderate-to-severe Graves' orbitopathy therapy should send patients to a combined thyroid-eye clinic for evaluation and management. Thyroid dermopathy is an uncommon extrathyroidal symptom of Graves' disease that occurs in 1-4% of thyroid ophthalmopathy patients. Almost every patient has concurrent ophthalmopathy. The lesions are distinguished by slightly pigmented thicker skin that mostly affects the pretibial region.<sup>8</sup> As like on this patient, she had blurred vision that accompanied with visible mass on her neck. When watching, the patient feels blur and pain in her right eyes. The patient's pain has been felt since 1 year ago and has gotten worse in the last 2 months. The patient is also often get anxiety since last month and feels loss of appetite. The patient was not obese, had no history of trauma to the eye and neck.

Thyroid function tests in peripheral blood are used to detect thyroid status. Thyroid-stimulating hormone (TSH), which is generated by the pituitary gland, as well as the thyroid hormones thyroxine (T4) and triiodothyronine (T3), may be easily tested using well-established assays. Subclinical hyperthyroidism is defined as unusually low TSH values with normal free T4 and total or free T3 concentrations. Observational studies, on the other hand, commonly diagnose

subclinical hyperthyroidism using just TSH and free T4 levels since T3 levels are usually within the reference range if free T4 levels are. T3 toxicosis is a rare type of overthyroidism in which free T4 levels are normal but T3 levels are excessive (Khan et al., 2020). In the patient that underwent laboratory examination it was found that TSHs levels were 0.085 uIU/mL, FT4 levels were 12.8 pmol/L, creatinine was 0.9 mg/dL, Calcium was 1.23 mmol/L, Natrium 134 mmol/L, Kalium 3.30 mmol/L. Decrease amount of TSHs is found on this laboratory examination which mean there is an abnormality of excessive amount of thyroid production (Fatourechi, 2012).

The majority of thyroid nodules are asymptomatic, discovered by chance, and cytologically benign. Thyroid ultrasonography is the most sensitive diagnostic technique for nodular thyroid disease patients. As a result, it is critical to use the ultrasonic characteristics to identify nodules that require fine-needle aspiration cytology. Thyroid nodules can be detected and evaluated using high-resolution ultrasonography (US). US is used to assess the size and characteristics of thyroid nodules and the existence of lymph node metastases in the neck. It also makes guided fine-needle aspiration possible. (US-FNA). Spiculated edges, microcalcifications, a taller-than-wide form, and significant hypoechoogenicity are the most consistent malignancy characteristics of thyroid nodules in the United States. Increased nodular vascularization has not been recognized as a risk factor for cancer. Thyroid elastosonography (USE) is another technique for identifying thyroid nodules (Rago & Vitti, 2022).

The most common underlying cause of Hyperthyroidism is grave disease(GD), and it is estimated that there is 20 to 50 per 100,000 case per year, It is a complex illness with genetic, environmental, and endogenous influences (Smith & Hegedüs, 2016). The condition is most common between the ages of 30 and 50, but it can develop at any age and affects women more frequently than males just like this patient on our report that is woman and 45 years old (Piantanida, 2017). Circulating autoantibodies directed against the thyrotropin receptor (TSHR) mimic the action of TSH and excessively activate thyroid follicular cells, stimulating the secretion of thyroid hormones (triiodothyronine and thyroxine), thereby inducing thyroid growth and vascularization. These mechanisms cause hyperthyroidism symptoms such as anxiety, tiredness, nervousness, weight loss, moist skin, hair loss, muscular weakness, and palpitations to occur (Lin et al., 2017). Extrathyroidal symptoms include dermatopathy, acropachy, and ophthalmopathy, as well as edematous-infiltrative alterations involving orbital soft tissues. Cytokine production and inflammation, hyaluronan synthesis, adipogenesis, and myofibrillogenesis are the primary mechanisms implicated in the pathophysiology of thyroid-associated orbitopathy (Malik & Wadhwa, 2016). The orbital adipose tissue and extraocular muscular fiber tissue are the primary sources of continuous inflammation. Activated mononuclear cells, such as T cells, penetrate the orbital tissues, as do plasmacytes, macrophages, and mast cells to a lesser level. IFN-, IL-1 (IL-5) and leukoregulin (lymphokine generated by active lymphocytes) are cytokines that cause the production of glycosaminoglycans (GAG). GAG buildup causes extraocular muscular edema. As a result, the eyeball extends beyond the orbit's bony margins. Furthermore, optic nerve compression can develop, leading in optic neuropathy, as well as decreased venous and lymphatic outflow from the orbit that cause proptosis (Łacheta et al., 2019).

Ocular proptosis measurement is critical in the identification of orbital illnesses such as Graves' orbitopathy (GO), orbital malignancy, and orbital fracture. There are numerous instruments available for determining the degree of proptosis. The proptosis values evaluated by 3D reconstruction software, CT, and Hertel exophthalmometer were closely linked yet differed significantly ( $p < 0.001$ ). The degree of change in proptosis following orbital decompression, on the other hand, did not differ across the three observations ( $p = 0.153$ ). The 3D reconstruction software, CT, and Hertel exophthalmometer intra-observer correlation coefficients were 0.997, 0.942, and 0.953, respectively. The intra-observer correlation coefficients of CT and Hertel exophthalmometers dropped in patients with strabismus to 0.895 and 0.920, but the intra-observer correlation coefficient of 3D reconstruction software did not change at 0.996. therefore CT and 3D reconstruction seems have more reliable value to measured proptosis, furthermore even for eyeball deviation (Huh et al., 2020). For this reason another examination is perform in this patient that was, Head CT-Scan with contrast orbita centration, on this examination brain edema and proptosis on occuli dextra were found which is complication that can occur on hyperthyroidism patient.

The therapy of GO is determined by the patient's symptoms and severity, and includes basic, medicinal, and surgical therapies. The optimum treatment objective is to reduce the risk of visual problems, limit side effects, avoid surgical treatments, restore thyroid function, and prevent the progression or recurrence of GO. Early identification and preventative therapy, such as the elimination of modifiable risk factors, may minimize the prevalence of GO and alter its clinical symptoms. Regardless of severity, basic therapies such as artificial tears (ointment is required when corneal exposure occurs), dark glasses, parasol, lifting the pillow at sleep, and reducing risk factors are often advised. Most moderate GO patients do not have increasing growth of the afflicted extraocular muscles, therefore a wait-and-see approach is possible. If GO is active, a small number of moderate GO patients may be recommended for low-dose immunomodulation. Patients with moderate-to-severe and active GO who have visible symptoms and active illness are mostly treated with medication or orbital irradiation treatment (Li et al., 2023).

Recently there is new drug named Teprotumumab, an insulin-like growth factor-1 receptor inhibitor, lowers TSH-stimulated proinflammatory cytokine production in isolated fibrocytes and dramatically lowers TSH-R and IGF-1R expression in fibrocytes. Teprotumumab reduced ptosis, diplopia, CAS score, and quality of life in patients with moderate-to-severe GO and had a positive safety profile, at 2017, a randomized, double-blind, placebo-controlled experiment was undertaken at 22 centers throughout the world. Teprotumumab improved proptosis in moderately to severely active GO patients with just a 5% complication rate. At the 24th week of a placebo-controlled teprotumumab phase III clinical study, exophthalmos reduced by 2 mm in 82.9% of moderately to highly active GO patients.

Teprotumumab was designated as a "breakthrough therapy" by the FDA because of its disease-modifying capabilities (Li et al., 2023). Current data supports the use of intravenous corticosteroids to reduce CAS in individuals with moderate to severe GO. Intravenous pulse corticosteroid treatment shows a minor but statistically significant benefit over oral medication in terms of side effects. Clinical effectiveness of somatostatin analogs is modest (Li et al., 2023).

A course of anti-thyroid drugs (ATD) is the most common first-line treatment for Graves' hyperthyroidism. Relapses of hyperthyroidism, on the other hand, are common (30-70%). Because Graves' disease is an autoimmune illness, immunosuppressive medication for active Graves' orbitopathy (GO), such as intravenous pulse therapy, may reduce relapses after ATD discontinuation. The study that conducted by Moli et al, was determine the recurrence rate in Graves' disease patients who got or did not receive parenteral methylprednisolone (MPDS) for GO therapy in addition to standard ATD. The most significant predictor that independently linked with a lower probability of hyperthyroidism recurrence was MPDS therapy (HR = 0.53, 95% C.I. = 0.31-0.89). FT3 and female sex were also independent protective variables, and age was practically significant (p = 0.062) (Le Moli et al., 2020). MPDS had a very high effectiveness in individuals aged 40 years (42.1% decrease in relapses, p 0.01) recurrence of Graves' hyperthyroidism was significantly declined in individuals treated with MPDS pulse treatment for GO as in this case the patient were treated with 0.75 g intravenous methylprednisolone for 6 weeks continued with 0.5 g intravenous methylprednisolone for another 6 weeks. The patient show a significant improvement after this intravenous methylprednisolone pulse therapy was administered.

## CONCLUSION

Hyperthyroid is a disorder of the thyroid glands in which there is excessive secretion of thyroid hormone from one or more thyroid glands which ultimately causes large amount of triiodothyronine and thyroxine production, thereby inducing thyroid growth and vascularization. These mechanisms cause symptoms of hyperthyroidism such as anxiety, tiredness, nervousness, weight loss, moist skin, hair loss, muscular weakness, and palpitations. Extrathyroidal symptoms include dermopathy, acropachy, ophthalmopathy, and edematous-infiltrative alterations involving orbital soft tissues. Cytokine production and inflammation, hyaluronan synthesis, adipogenesis, and myofibrillogenesis. To diagnose, it is necessary to carry out laboratory tests such as TSHs, FT4, and electrolyte levels in the blood. Neck ultrasound and CT-scan of the Head with contrast orbita centration also need to be done to determine the location of proptosis and complication of hyperthyroidism. For management, Basic therapies such as artificial tears (ointment is required when corneal exposure occurs), dark glasses, parasol, lifting the pillow at sleep, and reducing risk factors are often advised. Patients with moderate-to-severe and active GO who have visible symptoms and active illness are mostly significantly treated by intravenous methylprednisolone pulse therapy.

## REFERENCES

- De Leo, S., Lee, S. Y., & Braverman, L. E. (2016). Hyperthyroidism. *The Lancet*, 388(10047), 906–918.
- Fatourechi, V. (2012). Thyroid dermopathy and acropachy. *Best Practice & Research Clinical Endocrinology & Metabolism*, 26(4), 553–565.
- Huang, Y., Fang, S., Zhang, S., & Zhou, H. (2020). Progress in the pathogenesis of thyroid-associated ophthalmopathy and new drug development. *Taiwan Journal of Ophthalmology*, 10(3), 174.
- Huh, J., Park, S. J., & Lee, J. K. (2020). Measurement of proptosis using computed tomography based three-dimensional reconstruction software in patients with Graves' orbitopathy. *Scientific Reports*, 10(1), 14554.
- Khan, R., Sikanderkhal, S., Gui, J., Adeniyi, A.-R., O'Dell, K., Erickson, M., Malpartida, J., Mufti, Z., Khan, T., & Mufti, H. (2020). Thyroid and cardiovascular disease: a focused review on the impact of hyperthyroidism in heart failure. *Cardiology Research*, 11(2), 68.
- Łacheta, D., Miśkiewicz, P., Głuszko, A., Nowicka, G., Struga, M., Kantor, I., Poślednik, K. B., Mirza, S., & Szczepański, M. J. (2019). Immunological aspects of Graves' ophthalmopathy. *BioMed Research International*, 2019.
- Le Moli, R., Malandrino, P., Russo, M., Lo Giudice, F., Frasca, F., Belfiore, A., & Vigneri, R. (2020). Corticosteroid Pulse Therapy for Graves' Ophthalmopathy Reduces the Relapse Rate of Graves' Hyperthyroidism. *Frontiers in Endocrinology*, 11, 367.
- Li, X., Li, S., Fan, W., Rokohl, A. C., Ju, S., Ju, X., Guo, Y., & Heindl, L. M. (2023). Recent advances in graves ophthalmopathy medical therapy: a comprehensive literature review. *International Ophthalmology*, 43(4), 1437–1449.

- Lin, J.-D., Yang, S.-F., Wang, Y.-H., Fang, W.-F., Lin, Y.-C., Liou, B.-C., Lin, Y.-F., Tang, K.-T., & Cheng, C.-W. (2017). Associations of melatonin receptor gene polymorphisms with Graves' disease. *PLoS One*, *12*(9), e0185529.
- Malik, I., & Wadhwa, R. (2016). Percutaneous nephrolithotomy: current clinical opinions and anesthesiologists perspective. *Anesthesiology Research and Practice*, *2016*.
- Piantanida, E. (2017). Preoperative management in patients with Graves' disease. *Gland Surgery*, *6*(5), 476.
- Rago, T., & Vitti, P. (2022). Risk stratification of thyroid nodules: From ultrasound features to TIRADS. *Cancers*, *14*(3), 717.
- Şahlı, E., & Gündüz, K. (2017). Thyroid-associated ophthalmopathy. *Turkish Journal of Ophthalmology*, *47*(2), 94.
- Sajjadi-Jazi, S. M., Sharifi, F., Varmaghani, M., Meybodi, H. A., Farzadfar, F., & Larijani, B. (2018). Epidemiology of hyperthyroidism in Iran: a systematic review and meta-analysis. *Journal of Diabetes & Metabolic Disorders*, *17*, 345–355.
- Smith, T. J., & Hegedüs, L. (2016). Graves' disease. *New England Journal of Medicine*, *375*(16), 1552–1565.
- Wiersinga, W. M., Perros, P., Kahaly, G. J., Mourits, M. P., Baldeschi, L., Boboridis, K., Boschi, A., Dickinson, A. J., Kendall-Taylor, P., & Krassas, G. E. (2006). Clinical assessment of patients with Graves' orbitopathy: the European Group on Graves' Orbitopathy recommendations to generalists, specialists and clinical researchers. *European Journal of Endocrinology*, *155*(3), 387–389.
- Yang, I.-H., Rose, G. E., Ezra, D. G., & Bailly, M. (2019). Macrophages promote a profibrotic phenotype in orbital fibroblasts through increased hyaluronic acid production and cell contractility. *Scientific Reports*, *9*(1), 9622.

