

Retroperitoneal Abscess: A Case Series and Literature Review

Aditya Fajar Bahagiato^{1*)}, Jufriady Ismy²

^{1*)} Urology Division, Surgery Department, Faculty of Medicine, Universitas Padjadjaran, Hasan Sadikin Hospital, Bandung, Indonesia

² Urology Division, Surgery Department, Faculty of Medicine, Universitas Syiah Kuala, Zainoel Abidin General Hospital, Banda Aceh, Indonesia

ABSTRACT

Retroperitoneal abscess is one of the rare abscesses within the retroperitoneal space that has higher mortality and morbidity. The obscurity of exact clinical manifestations and diagnosis of the disease causes neglected inflammatory process which leads to worse progression. In this case series and literature review we describes four patients with retroperitoneal abscess. We report the clinical manifestation and treatment of retroperitoneal abscess. The patient often came with chief complaints of pain and feeling of fullness in the waist. CT scan usually revealed a hypodense lesion. The treatment consists of pharmacological treatment and surgical procedures. Nonspecific clinical manifestations often lead to misdiagnosis which causes the progression of disease. Early diagnosis and treatment is crucial for better outcome.

Keywords: Diabetes mellitus (DM); teripang bilalo (*Actinopyga mauritiana*); blood sugar levels; pancreatic histology

Corresponding author: Aditya Fajar Bahagiato
Urology Division, Surgery Department, Faculty of Medicine, Universitas Padjadjaran, Hasan Sadikin Hospital, Bandung, Indonesia
Jl. Pasteur No. 38, Pasteur, Kec. Sukajadi, Kota Bandung, Jawa Barat 40161
Email: adityabahagiato@gmail.com

INTRODUCTION

Abscess is defined as the presence of localized collection of pus due to infection or other foreign materials which can be formed in any body organ.(St., 2013) One of the rare abscesses with higher mortality and morbidity is retroperitoneal abscess, especially when the treatment is nonoptimal. The incidence of psoas abscess, one of retroperitoneal abscess, has been known to increase since the invention of Computed Tomography (CT). In 2017, the incidence of psoas abscess in Japan, England, The Netherlands, and the USA were 111.5, 9.5, 35.1, and 42.6 cases per 1,000,000 population, respectively.(Sato et al., 2021)

Retroperitoneal abscess is the presence of abscess in the retroperitoneal space which is divided into two classifications, which are primary and secondary. The occurrence of this abscess tends to be happened hematogenously, but organ pathologies also play role in the development of secondary retroperitoneal abscess.(Aslan et al., 2018) The clinical manifestations of retroperitoneal abscess tends to be nonspecific.(Huang et al., 2015) The adjacent organs are potential to be infected rapidly such as perinephric space, the psoas muscle, lateral abdominal wall, and the lower extremities.(Aljohani et al., 2020) Management of retroperitoneal abscess can be conservatively delivered by using pharmacology treatment such as antibiotic, as also operative treatment as the definitive management.(Mosquera et al., 2019)

This study aimed to describes four patients with retroperitoneal abscess and discuss the clinical manifestation and treatment of retroperitoneal abscess.

RESEARCH METHOD

Case Presentations

Case 1

A 40-year-old woman came to the Emergency Department complaining of pain and fullness in the left flank region one week ago. One month ago, the patient fell on the floor and hit the left hip. The patient has been treated and given antibiotics, but the complaints persist and worsen over time. The patient had no history of diabetes mellitus, hypertension, or tuberculosis. The results of the abdominal CT scan with contrast showed a thick-walled hypodense lesion with cystic, lobulated, and well-defined components. In intraoperative findings, pus fluid was obtained as much as ± 800 cc in the perirenal area. The patient was given antibiotics, and the patient was discharged seven days postoperatively.

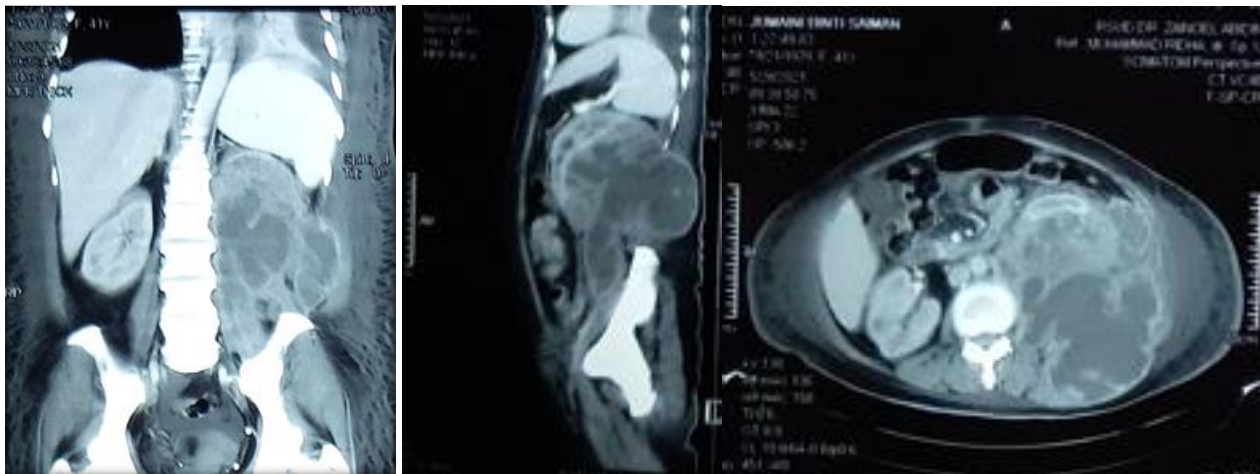


Figure 1: Abdominal Contrast CT Scan with anterior, lateral, and sagittal section showing thick-walled hypodense lesion with a cystic component, lobulated, well-defined.

Case 2

A 55-year-old woman came with complaints of fullness in the right flank and fever felt since four days ago. Previously, the patient complained of low back pain since one month ago, which was felt suddenly. The patient has a history of diabetes that has been felt for six months but has never been controlled. He denied a history of hypertension and tuberculosis. Previous surgical history was denied. A hypodense lesion was demarcated in the psoas major muscle from a CT scan with contrast, describing an abscess. In intraoperative findings, 800 cc of pus was found in the perirenal area. Postoperatively, the patient was given antibiotics and discharged after six days of treatment.

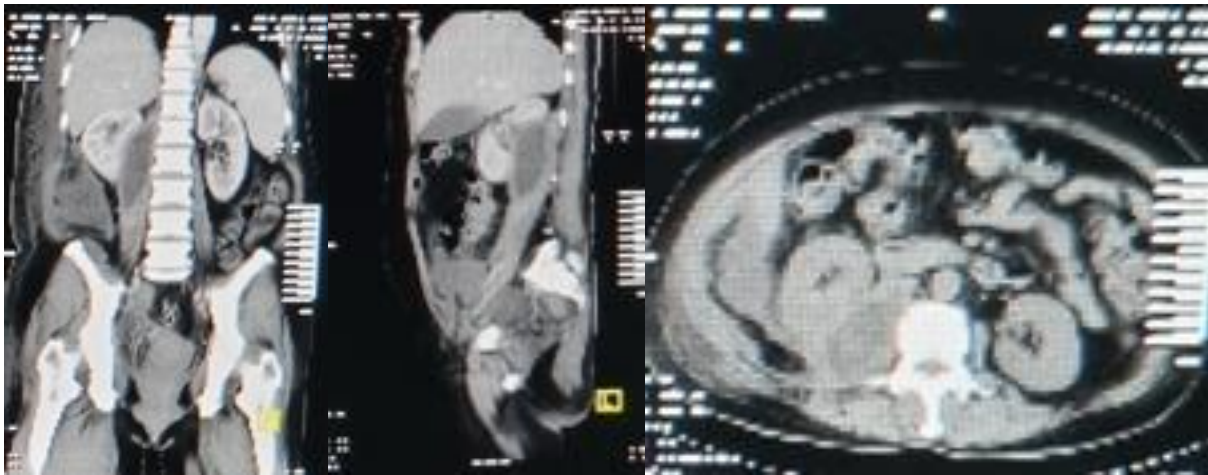

Figure 2: Abdominal Contrast CT Scan with anterior, lateral, and sagittal section showing an abscess with a well-defined hypodense lesion on the psoas major muscle

Case 3

A 52-year-old woman came with complaints of pain and fullness in the left flank three days ago. Previously, the patient complained of a high fever for seven days accompanied by low back pain. The patient underwent gallstone surgery one month ago. The patient has had a history of controlled diabetes since eight years ago, and there is no history of hypertension and tuberculosis. A CT scan with contrast found that there was a hypodense lesion in the left perirenal area and a well-defined hyperdense lesion in the left proximal ureter measuring 12x6 mm. In intraoperative findings, 200 cc of pus was found in the perirenal area and a left proximal ureteral stone measuring 12x6 mm. During his treatment, the patient died of suspected hospital-acquired pneumonia (HAP) during postoperative care.

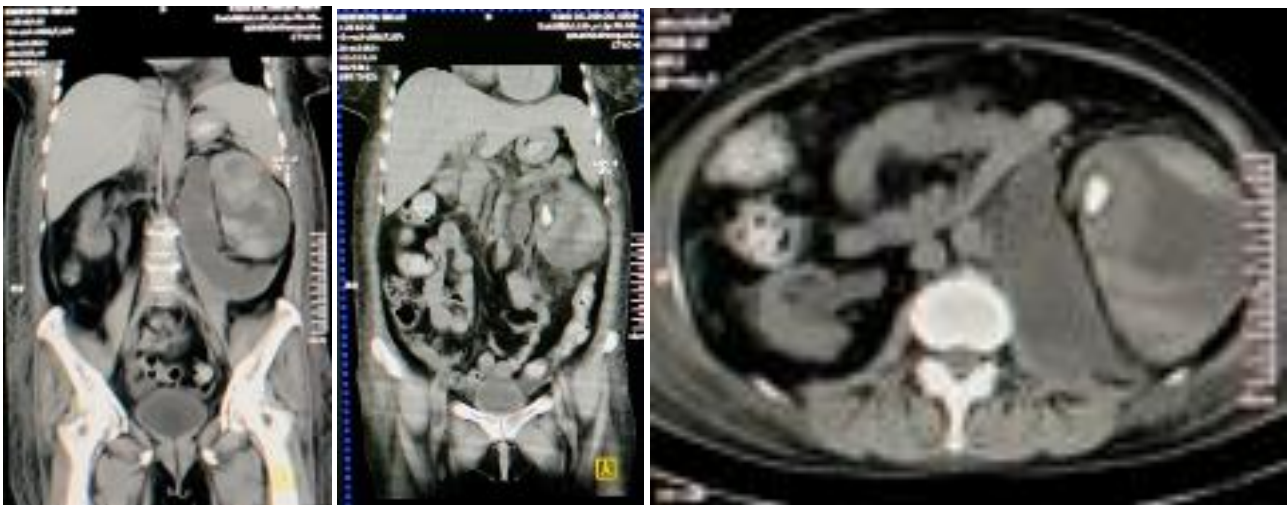

Figure 3: Abdominal Contrast CT Scan with anterior, lateral, and sagittal section showing hypodense lesion in the left perirenal area and a well-defined hyperdense lesion in the left proximal ureter measuring 12x6 mm

Case 4

A 28-year-old woman comes with complaints of high fever and flank pain since three weeks ago and has worsened in the last three days. History of diabetes, hypertension, and tuberculosis was denied. Two years ago, the patient underwent surgery for removal of right kidney stone. After surgery, the patient has had no complaints. From a CT scan, a hypodense lesion in the right perirenal area was demarcated. In intraoperative findings, 350 cc of pus was found in the perirenal area. Postoperatively the patient was given antibiotics, and after seven days of treatment, the patient was discharged.

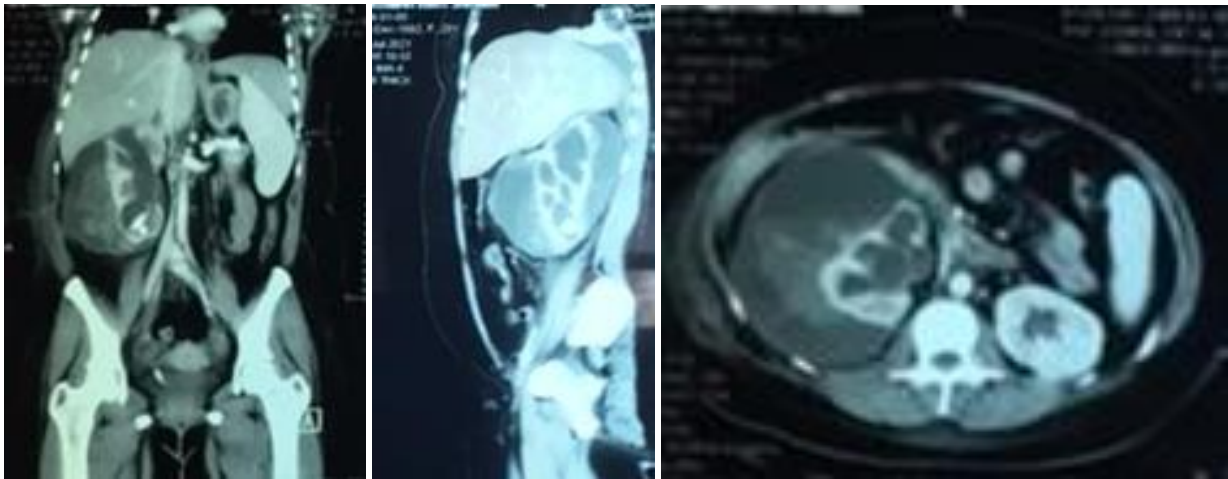


Figure 4: Abdominal Contrast CT-Scan with anterior, lateral, and sagittal section showing hypodense lesion in the right perirenal area

RESULTS AND DISCUSSION

Retroperitoneal abscess is a disease characterized by the presence of abscess within the retroperitoneal zone. This zone is divided into three spaces: anterior pararenal space, perirenal space, and posterior pararenal space. The incidence has been known to happen in people aged 30 – 50 years of age, dominating on male. (Huang et al., 2015) However, the epidemiologic data is scarce due to its rare incidence.

Etiology and Pathogenesis

The majority of cases were previously known to be caused by staphylococci as a flora of the skin. However, other microorganisms found in retroperitoneal abscess are vary, including *E. coli*, *Klebsiella pneumoniae*, *Proteus Mirabilis*, *Mycobacterium tuberculosis*, and *Pseudomonas sp.* The invention of antibiotic has decreased the likelihood of primary abscess. A study by Rahmi et al. had found that 86% cases were happened secondarily in which 63% of the patients were caused by GUS infection, 26% from musculoskeletal, 4% from GIS, and the others were hardly identified. Hence, the presence of urinary system obstructions and previous urological surgeons increase the risk of retroperitoneal abscess. (Aslan et al., 2018) The predisposing factors include immunocompromised states such as diabetes mellitus and Human Immunodeficiency Virus (HIV), malignancy, obesity, trauma, long-term use of immunosuppressive therapy, and other urological and gastrointestinal procedures. (Akhan et al., 2020; Huang et al., 2015)

Genitourinary System Infection

The extension of genitourinary tract infection is the most common aetiology causing retroperitoneal abscesses. (Ishan et al., 2020) Common causes of retroperitoneal abscess include fulminant pyelonephritis, hematogenous dissemination, dissemination from adjacent organ, perinephric abscess, and renal abscess. The renal abscess grows within fibrous capsule and renal fascia, and finally end as retroperitoneal infection if not treated optimally. (Z. Li et al., 2021; Tufano et al., 2020) Kidney stones with history of urological surgery and or diabetes also predisposes the likelihood of retroperitoneal abscess. Ascending infection from genitourinary tract, especially in female, is another common aetiology for retroperitoneal abscess. (Alfarissi et al., 2021) Cervix carcinoma also tends to infiltrate the pelvic organ which finally metastasizes to the paracaval retroperitoneum. (Mehdorn et al., 2016)

Musculoskeletal infection

Retroperitoneal abscess is highly probable to happen due to bone infections such as Pott's disease and osteomyelitis. The disease is spread hematogenously from distant loci in abdominal and pelvic surgeries. (Garcia-Prieto & Casillas-Villamor, 2018; Ishan et al., 2020) Spinal osteomyelitis can also generate paraspinal abscess within retroperitoneal spaces which leads to retroperitoneal abscess. (Z. Li et al., 2021) Meanwhile, psoas abscess can spread the infection from upper muscle part to hip joint due to its anatomical location. Psoas muscle origins from lateral part of 12th thoracic vertebrae to 5th lumbar vertebrae and finally ends as insertion to the iliacus into lesser trochanter. (Snell, 2018)

Gastrointestinal System Infection

Retroperitoneal abscess can be extended both primarily and secondarily. The probable causes include perforated appendix, colorectal carcinoma, diverticular disease, Crohn's disease, and ingestion of foreign body. (Aljohani et al., 2020; Hesketh et al., 2021; Parikh et al., 2018) Any disease within retroperitoneal spaces is possible to be perforated. One

of the example is colorectal carcinoma which develops retroperitoneal abscess by invading the muscle layer. This layer is highly prone to be perforated. The diffusion of faeces and bacteria from colon to the retroperitoneal space will finally causes retroperitoneal infections. Perforation of colon also can be found as pneumoperitoneum, pneumomediastinum, and iliopsoas abscess.(Z. Li et al., 2021; Ruscelli et al., 2018) Other diseases such as Crohn disease, appendicitis, intraperitoneal infection, and cancer can also cause iliopsoas abscess within the retroperitoneal space.(Y. Li et al., 2017)

Iatrogenic

Any surgical procedures such as lumbar puncture, wound care, and surgical complications might cause iatrogenic retroperitoneal abscess. Associated medical conditions related to this aetiology include duodenal fistula, bile duct injury, pancreatitis, appendicitis, and infection of colon and rectum. Post-cholecystectomy cholecystitis also has a potency to cause retroperitoneal abscess after Kocher maneuver which escalate the likelihood of micro-perforation the retroperitoneal space.(Alvarado et al., 2019) History of transanal minimally invasive surgery and transanal endoscopic microsurgery should be considered as one of retroperitoneal abscess's risk factors.(Raney & Raman, 2017) Other iatrogenic causes of retroperitoneal abscess include lumbar acupuncture, (Lee et al., 2019)

Classification

Retroperitoneal abscess is classified into two categories, they are primary and secondary. Primary abscess is disseminated via hematogenous or lymphatic spread into any body organs in the retroperitoneal space.(Atif et al., 2018) While secondary infection is originated from adjacent organs within the space, such as genitourinary infection and gastroenterology infection (diverticulitis, pancreatitis, appendicitis, biliary, and peptic ulcer). (Huang et al., 2015) Psoas abscess as one of retroperitoneal abscess can be identified both as primary and secondary due to penetrating trauma, penetration of spinal osteomyelitis or tuberculosis, renal infection, and inflammatory bowel disease.(Aslan et al., 2018; Elshazzly et al., 2018) The most common cause of psoas abscess is *Staphylococcus aureus* (88%), followed by streptococci and *E. coli*.(Palacios-Zertuche et al., 2016) Based on the anatomical location, retroperitoneal abscess also can be classified into perinephric, superior, pelvic, and musculoskeletal. (Mosquera et al., 2019)

Diagnosis

The diagnosis of retroperitoneal space is frequently delayed or misdiagnosed since the clinical manifestations of retroperitoneal abscess is nonspecific. The fact that the process is developed in retroperitoneally causes minimum signs. Most patients complain of fever, back pain, nausea, vomiting, and abdominal pain.(Z. Li et al., 2021; Park & You, 2021) Extension to the thigh, groin, or scrotum, can lead to other clinical manifestations after the average of 13 days since the onset of abdominal pain. As the disease progresses, other clinical features such as presacral pain, local tenderness, hypostatic oedema, malnutrition, and weight loss develop.(Z. Li et al., 2021) A case report by Atif et al. reported hip joint manifestation due to the extension of infection from psoas abscess to the hip capsule.(Atif et al., 2018) Spondylitis-associated psoas abscess will show classic signs such as fever, flank pain, and limp.

Laboratory examination might be needed to rule out the existence of infection by detecting increased inflammatory markers. Gram staining, ascites fluid culture, and histopathological examination on biopsy-sample obtained laparoscopy are superior diagnostic tests in confirming the exact aetiology of retroperitoneal abscess.(Aljohani et al., 2020; Palacios-Zertuche et al., 2016) Radiography remains as the most effective diagnostic tool to detect retroperitoneal abscess, such as Computed Tomography (CT), Magnetic Resonance Imaging (MRI), and abdominal sonography.(Huang et al., 2015) The accuracy rate of CT-Scan to diagnose retroperitoneal abscess is 100% hence CT-Scan becomes the gold standard for diagnosis. Loss of psoas line or existence of opaque density indicates retroperitoneal abscess.(Alfarissi et al., 2021) Pus culture is the definitive diagnostic test in confirming the exact aetiology of retroperitoneal abscess.(Aljohani et al., 2020) When ingestion of foreign body is clinically suspected, laparoscopy can be performed to explore and confirm the diagnosis.(Parikh et al., 2018)

Based on clinical finding, the diagnostic criteria for diagnosing retroperitoneal infection is as follow: 1) Fever, tachycardia, tachypnoea, excessive sweating, and other systemic infection manifestations, 2) Radiating pain in lumbosacral area, 3) Positive sign of psoas major muscle and iliopsoas muscle, 4) Abnormal inflammatory markers, and 5) Relevant finding in imaging and surgical output. (Z. Li et al., 2021)

Treatment

Retroperitoneal abscess is highly risky to cause mortality without treatment. The treatment is divided into pharmacological treatment and surgical procedures.

Pharmacological treatment

The crucial pharmacological treatment in treating retroperitoneal abscess is antibiotic. Antibiotic alone is sufficient to treat abscess with the size of less than 3 cm. (Aslan et al., 2018) Empiric antibiotic is only given as the initial treatment which needs to be replaced by definitive antibiotic according to microbiology culture.(Ishan et al., 2020)

Surgical Procedures

Image-guided drainage is known as the most used management for retroperitoneal abscess. Percutaneous drainage, which is guided under imaging, has been considered as the first line treatment for intra-corporeal fluid drainage with minimal invasion. (Aslan et al., 2018) This drainage technique is indicated for pyogenic retroperitoneal abscesses with diameter of < 4 cm, poor condition, and unresponsive with systemic antibiotic. However, misdiagnosis, catheter withdrawal, inadequate catheters, unsterile procedures, and improper use of antibiotics might cause the recurrence of abscess postoperatively. (Akhan et al., 2020) The advantages of CT-guided percutaneous abscesses drainage include shorter procedure time, less blood loss, real-time assessment using CT-Scan, and the existence of pus to be sent for laboratory examination. (Zou et al., 2017) Larger abscess size requires surgical drainage such as extensive debridement and musculocutaneous flap such as Lumbar Artery Perforator (LAP) for the surface closure. (Alfarissi et al., 2021)

In the case of superior retroperitoneal abscess, retroperitoneoscopic approach is highly suggested to decrease the likelihood of dissemination to other retroperitoneal spaces. (Mosquera et al., 2019) In case of tuberculous abscess, the pus has to be drained using catheter to minimize the recurrence rate. (Akhan et al., 2020) Besides, posterolateral percutaneous endoscopic surgery to treat retroperitoneal abscess with the involvement of spine has to be done in caution to not damage the exiting nerve root. (Iida et al., 2019) Treating the origin source of infection is crucial to make sure total management of retroperitoneal abscess. (Huang et al., 2015)

Complication and Prognosis

There were 12.4% cases of retroperitoneal abscess underwent recurrent process. The recurrence were more reported in patients with renal failure. (Yamamichi et al., 2017) Complications of retroperitoneal abscess include pyelonephritis fistula, sepsis, multiorgan failure, and higher mortality. (Aljohani et al., 2020; Aslan et al., 2018) For instance, iliopsoas abscess can spread the infection via iliopsoas bursa or iliopsoas muscle to the hip joint. (Scaglia et al., 2020) Having said that, early diagnosis and treatment is fundamental and crucial to produce better prognosis. (Z. Li et al., 2021) Our series report no complication of three patients, but one patients reported having HAP infections that may be burdened from its own comorbidities including diabetes mellitus.

CONCLUSIONS AND SUGGESTIONS

Given the finding that we found, retroperitoneal abscess is an insidious inflammation process within the retroperitoneal spaces. The aetiologies vary from genitourinary infection, gastrointestinal infection, musculoskeletal infection, and iatrogenic. The complexity of nonspecific clinical manifestations lead to early misdiagnosis and advanced process of disease. Management of retroperitoneal abscess is consisted of pharmacological treatment and surgical procedures based on the indication. Early diagnosis and treatment is crucial for better outcome. Our cases showed there's positive response of three patients after given antibiotics post-operatively, last patients were died because of HAP infections and comorbidities.

Acknowledgment

Technical assistance and advice can be described at the end of the text. Then the names of individuals that are included in this section, the author is responsible for the written consent of every person who communicates personally or recognized by the individual in the text.

REFERENCES

- Akhan, O., Durmaz, H., Balci, S., Birgi, E., Çiftçi, T., & Akıncı, D. (2020). Percutaneous drainage of retroperitoneal abscesses: Variables for success, failure, and recurrence. *Diagnostic and Interventional Radiology*, 26(2), 124–130. <https://doi.org/10.5152/dir.2019.19199>
- Alfarissi, F., Putri, N. M., & Atmoko, W. (2021). Multidisciplinary approach for large retroperitoneal abscess management: A case report. *International Journal of Surgery Case Reports*, 80(71), 105668. <https://doi.org/10.1016/j.ijscr.2021.105668>
- Aljohani, E., Almadi, F., & Alshehri, A. (2020). Fournier Gangrene, Empyema and Retroperitoneal Abscess as a Rare Complication of Perforated Appendicitis: A Case Report. *Juniper Online Journal of Case Studies*, 11(1). <https://doi.org/10.19080/JOJCS.2020.11.555804>
- Alvarado, M. U., Colindres, C. A., Pinto, L. J., Padilla, C. G., & Reyes, C. E. (2019). Secondary psoas abscess after an open cholecystectomy and a common bile duct exploration. *International Journal of Surgery Case Reports*, 63, 53–55. <https://doi.org/10.1016/j.ijscr.2019.08.026>

- Aslan, R., Özgökçe, M., Eryılmaz, R., Duran, M. A., Yıldızhan, M., & Taken, K. (2018). Retroperitoneal abscesses: Origin, ethiology and percutaneous treatment. *Eastern Journal of Medicine*, 23(4), 269–274. <https://doi.org/10.5505/ejm.2018.69875>
- Atif, M., Malik, A. T., & Noordin, S. (2018). Psoas abscess masquerading as a prosthetic hip infection : A case report. *International Journal of Surgery Case Reports*, 42, 17–19. <https://doi.org/10.1016/j.ijscr.2017.11.054>
- Elshazzly, M., Bashjawish, F., Shahid, M. A., Marrero, D. A., & Horowitz, J. (2018). A challenging case of retroperitoneal abscess in a post-partum Crohn's disease patient. *American Journal of Case Reports*, 19, 773–777. <https://doi.org/10.12659/AJCR.909545>
- Garcia-Prieto, F., & Casillas-Villamor, A. (2018). Psoas Abscess Associated with Pubic Symphysis Osteomyelitis. *American Journal of Medicine*, 131(9), e381–e382. <https://doi.org/10.1016/j.amjmed.2018.03.028>
- Hesketh, R. L., Fong, M., Shepherd, S., & Kalidindi, V. (2021). Acute appendicitis and retroperitoneal abscess: rare complications of sigmoid diverticulitis. *Radiology Case Reports*, 16(8), 1961–1964. <https://doi.org/10.1016/j.radcr.2021.04.075>
- Huang, S. H., Lo, W. O., Lin, C. M., Hsieh, T. S., Wang, S. F., Tsai, S. W., & Chen, K. C. (2015). Retroperitoneal abscess: 7-year experience of 29 cases in a tertiary care center in Taiwan. *Urological Science*, 26(3), 218–221. <https://doi.org/10.1016/j.urols.2015.01.009>
- Iida, K., Yoshikane, K., Tono, O., Tarukado, K., & Harimaya, K. (2019). The effectiveness of a percutaneous endoscopic approach in a patient with psoas and epidural abscess accompanied by pyogenic spondylitis: A case report. *Journal of Medical Case Reports*, 13(1), 1–6. <https://doi.org/10.1186/s13256-019-2193-6>
- Ishan, U. G. H., Thilakasiri, M. C. K., Weeratunga, P. N., & Lanerolle, R. D. (2020). Successful Medical Management of a Retroperitoneal Abscess: A Difficult Diagnosis in Pyrexia of Unknown Origin. *Case Reports in Infectious Diseases*, 2020, 1–5. <https://doi.org/10.1155/2020/6174293>
- Lee, H., Sung, K., & Cho, J. (2019). Retroperitoneal abscess with pylephlebitis caused by lumbar acupuncture: A case report. *BMC Surgery*, 19(1), 1–5. <https://doi.org/10.1186/s12893-019-0613-6>
- Li, Y., Funakoshi, H., Shiga, T., & Fujitani, S. (2017). Iliopsoas abscess. *Cleveland Clinic Journal of Medicine*, 84(11), 833–834. <https://doi.org/10.3949/ccjm.84a.17002>
- Li, Z., Tang, Y., Wang, P., & Ren, J. (2021). Diagnosis and Treatment of Retroperitoneal Infection. *Surgical Infections*, 22(5), 477–484. <https://doi.org/10.1089/sur.2020.126>
- Mehdorn, M., Petersen, T. O., Bartels, M., Jansen-Winkel, B., & Kassahun, W. T. (2016). Psoas abscess secondary to retroperitoneal distant metastases from squamous cell carcinoma of the cervix with thrombosis of the inferior vena cava and duodenal infiltration treated by Whipple procedure: A case report and review of the literature. *BMC Surgery*, 16(1), 1–6. <https://doi.org/10.1186/s12893-016-0169-7>
- Mosquera, M. S., Antonia, M., González-orocho, A., Rivera, C. J., & Cabrera, P. (2019). Retroperitoneoscopic drainage of a retroperitoneal abscess when open surgery is not an option: a novel surgical technique. *9(3)*, 60–62. <https://doi.org/10.15406/mojcr.2019.09.00305>
- Palacios-Zertuche, J. T., Limas-Rodríguez, Q. G., González-Cantú, C. M., Pérez-Salazar, D. A., Saldivar-Martínez, D. E., & Muñoz-Maldonado, G. E. (2016). Case report: Intestinal tuberculosis with perforation of the colon and psoas abscess associated with *Escherichia coli* ESBL. *Medicina Universitaria*, 18(72), 165–168. <https://doi.org/10.1016/j.rmu.2016.05.005>
- Parikh, R., Tsakanov, S., & Jamnagerwalla, M. (2018). Retroperitoneal abscess caused by foreign body ingestion. *ANZ Journal of Surgery*, 88(12), E849–E850. <https://doi.org/10.1111/ans.13930>
- Park, S., & You, M. W. (2021). Retroperitoneal abscess and retroperitoneum arising from a gastric intramural abscess: A case demonstrating the gastric bare area. *Korean Journal of Internal Medicine*, 36(1), 231. <https://doi.org/10.3904/kjim.2020.112>
- Raney, A., & Raman, S. (2017). Retroperitoneal abscess after transanal minimally invasive surgery: Case report and review of literature. *Journal of Coloproctology*, 37(4), 323–327. <https://doi.org/10.1016/j.jcol.2017.06.007>
- Ruscelli, P., Renzi, C., Polistena, A., Sanguinetti, A., Avenia, N., Popivanov, G., Ciocchi, R., Lancia, M., Gioia, S., & Tabola, R. (2018). Clinical signs of retroperitoneal abscess from colonic perforation. *Medicine (United States)*, 97(45), 1–6. <https://doi.org/10.1097/MD.00000000000013176>
- Sato, T., Kudo, D., & Kushimoto, S. (2021). Epidemiological features and outcomes of patients with psoas abscess: A retrospective cohort study. *Annals of Medicine and Surgery*, 62(January), 114–118. <https://doi.org/10.1016/j.amsu.2021.01.040>
- Scaglia, M., Lugani, G., Cassini, M., Ambrosini, C., & Magnan, B. (2020). Delayed diagnosis and treatment of a psoas abscess as a link between spondylodiscitis and septic necrosis of the femoral head: A case report. *Acta Biomedica*, 91(July 2018), 241–247. <https://doi.org/10.23750/abm.v91i4-S.9627>
- Snell, R. S. (2018). *Clinical Anatomy by Systems*. Lippincott Williams & Wilkins.
- St., L. (2013). *Mosby's medical dictionary 9th ed*. Mosby Elsevier.

- Tufano, A., Minelli, R., Di Lascio, G., Delicato, G., Baffigo, G., & Signore, S. (2020). Infected kidney stone progressing to perinephric abscess and thoracic empyema. *Archivio Italiano Di Urologia e Andrologia*, 92(3), 203–204. <https://doi.org/10.4081/AIUA.2020.3.203>
- Yamamichi, F., Shigemura, K., Kitagawa, K., Arakawa, S., Tokimatsu, I., & Fujisawa, M. (2017). Should We Change the Initial Treatment of Renal or Retroperitoneal Abscess in High Risk Patients? *Urologia Internationalis*, 98(2), 222–227. <https://doi.org/10.1159/000454887>
- Zou, D. X., Zhou, J. L., Zhou, X. X., & Jiang, X. B. (2017). Clinical efficacy of CT-guided percutaneous huge ilio-psoas abscesses drainage combined with posterior approach surgery for the management of dorsal and lumbar spinal tuberculosis in adults. *Orthopaedics and Traumatology: Surgery and Research*, 103(8), 1251–1255. <https://doi.org/10.1016/j.otsr.2017.07.015>