



**DIFFERENCES IN EFFECTIVENESS TEST OF CREAM AND GEL PREPARATIONS OF BLACK TURMERIC RHIZOME EXTRACT (*CURCUMA CAESIA ROXB.*) ON BURN WOUND HEALING IN WHITE RATS (*RATTUS NORVEGICUS*)**

**Authors:**

*Ni Nyoman Wahyu Udayani<sup>1\*</sup>, Ni Made Dharma Shantini Suena<sup>2</sup>, Ni Made Sukma Sanjiwani<sup>3</sup>*  
*<sup>1,2,3</sup> Faculty of Pharmacy, Universitas Mahasaraswati Denpasar, Jalan Kamboja No 11A, 80233, Denpasar*

*Corresponding Email: [udayani.wahyu@unmas.ac.id](mailto:udayani.wahyu@unmas.ac.id)*

**About the Author**

1. 1st Author : apt. Ni Nyoman Wahyu Udayani, S.Farm., M.Sc.  
Affiliation : Faculty of Pharmacy, Universitas Mahasaraswati Denpasar.  
Mailing address : Jalan Kamboja No 11A, Denpasar, Bali – Indonesia 80233  
Email of author : [udayani.wahyu@unmas.ac.id](mailto:udayani.wahyu@unmas.ac.id)  
Orcid ID : <https://orcid.org/0000-0003-0259-1759>  
Google Scholar URL : <https://scholar.google.com/citations?user=FIMB3Q8AAAAJ&hl=en&oi=ao>  
Phone number : 081246064647
- 2nd Author : apt. Ni Made Dharma Shantini S., S.Farm., M.Sc.  
Affiliation : Faculty of Pharmacy, Universitas Mahasaraswati Denpasar.  
Mailing address : Jalan Kamboja No 11A, Denpasar, Bali – Indonesia 80233  
Email of author : [dharmashantini@unmas.ac.id](mailto:dharmashantini@unmas.ac.id)  
Orcid ID : <https://orcid.org/0000-0001-5488-6298>  
Google Scholar URL : <https://scholar.google.com/citations?user=nJfnZEQAAAAJ&hl=en&oi=ao>  
Phone number : 08563740032
- 3rd Author : Ni Made Sukma Sanjiwani, S.Si., M.Si.  
Affiliation : Faculty of Pharmacy, Universitas Mahasaraswati Denpasar.  
Mailing address : Jalan Kamboja No 11A, Denpasar, Bali – Indonesia 80233  
Email of author : [sukmasanjiwani@unmas.ac.id](mailto:sukmasanjiwani@unmas.ac.id)  
Orcid ID : <https://orcid.org/0000-0002-3349-2457>  
Google Scholar URL : <https://scholar.google.com/citations?user=rEQAGDEAAAAJ&hl=en&oi=ao>  
Phone number : 082145212170

## ABSTRACT

Burns constitute a form of tissue damage and loss resulting from exposure to high-temperature sources, such as fire, hot water, chemicals, electricity, and radiation. Black turmeric (*Curcuma caesia*. Roxb) is identified as a natural remedy with empirical use for treating burns, owing to its composition of secondary metabolite compounds including alkaloids, flavonoids, and tannins. Topical formulations like creams and gels are commonly employed for burn treatment. This study focused on creating gel and cream formulations incorporating black turmeric extract at concentrations of 2%, 4%, and 8% to assess their effectiveness in burn wound healing. The objective was to investigate the impact of dosage forms on burn wound healing and identify the most efficacious preparation. Employing an experimental approach with a randomized pretest-posttest design involving a control group, the study comprised five test groups. Data analysis utilized the Kruskal-Wallis statistical test followed by post Mann-Whitney analysis. According to this study, P8 (8% extract concentration gel) and P3 (2% extract concentration cream) were the two preparations that healed burns the fastest, with 85% and 74%, respectively. This indicates that the topical dosage form influences the rate of burn healing in male white rats (*Rattus norvegicus*). Burns can be healed using either of the topical dosage forms (cream or gel), but the gel preparation works best.

Keywords: Burns; Black turmeric; Cream preparations; Gel preparations

## ABSTRAK

Luka bakar adalah jenis kerusakan dan kehilangan jaringan yang disebabkan oleh sumber daya yang memiliki suhu tinggi, seperti api, air panas, zat kimia, listrik, dan radiasi. Kunyit hitam (*Curcuma caesia*. Roxb) merupakan salah satu bahan alam yang secara empiris dapat digunakan untuk mengobati luka bakar, karena mengandung senyawa metabolit sekunder seperti alkaloid, flavonoid, dan tannin. Sediaan topikal krim dan gel merupakan sediaan yang umumnya digunakan untuk mengobati luka bakar. Pada penelitian ini dibuat formulasi sediaan gel dan krim dengan penambahan ekstrak kunyit hitam dengan konsentrasi 2%, 4% dan 8% untuk mengobati luka bakar. Tujuan dari penelitian ini adalah untuk mengetahui apakah ada pengaruh bentuk sediaan terhadap penyembuhan luka bakar dan untuk mengetahui sediaan yang paling efektif untuk menyembuhkan luka bakar. Penelitian ini menggunakan metode eksperimental dengan rancangan penelitian randomized pretest-posttest with control group design dengan menggunakan 5 kelompok uji, data yang diperoleh kemudian dianalisa dengan uji statistik Kruskal-Wallis, dengan menggunakan post Mann-Whitney. Menurut penelitian ini, P8 (gel konsentrasi ekstrak 8%) dan P3 (krim konsentrasi ekstrak 2%) adalah dua formulasi yang menyembuhkan luka bakar tercepat, dengan masing-masing 85% dan 74%. Hal ini menunjukkan bahwa bentuk sediaan topikal mempengaruhi tingkat penyembuhan luka bakar pada tikus putih jantan (*Rattus norvegicus*). Luka bakar dapat disembuhkan dengan menggunakan salah satu bentuk sediaan topikal (krim atau gel), tetapi formulasi gel bekerja paling baik.

Kata kunci : Luka Bakar; Kunyit Hitam; Sediaan Krim; Sediaan Gel

## INTRODUCTION

A burn is a form of tissue damage and loss resulting from exposure to a heat source, such as fire, hot water, chemicals, electricity, or radiation (Anggowarsito, 2014; Rismana et al., 2013). In the healing of burns, there are three phases: inflammation, proliferation, and remodeling (Cahaya Mentari, 2020; Fallo, 2019). Burns can cause damage to the skin tissue, increase capillary permeability, and in severe cases, affect the lungs, kidneys, and liver. They are injuries resulting from direct or indirect contact of body surfaces with hot objects (Anggowarsito, 2014).

*Curcuma caesia* Roxb., commonly known as black turmeric, is a plant that is believed to have medicinal properties for treating burns (Hidayat, G.A, Hidayat et al., 2016). Black turmeric is a plant that belongs to the *Zingiberaceae* family. Its medicinal properties are found in the hill roots of the Himalayas in North East Central India and in the hill forests of Sikkim in the north (Baghel et al., 2013). Black turmeric has a higher phytochemical content than other types of turmeric. Specifically, it contains higher amounts of curcumin, essential oils, carbohydrates, proteins, amino acids, steroids, glycosides, flavonoids, alkaloids, and tannins. These compounds, including flavonoids, alkaloids, tannins, and saponins, are secondary metabolites that aid in the healing of burns (Irham Rahman

Hakim, Fetri Lestari, 2021; Jibalathuull et al., 2017). Flavonoids and phenolic compounds are widely distributed in plants and have been reported to have several biological effects, including antioxidant and free radical capture abilities, as well as anti-inflammatory and anti-carcinogenic properties. Flavonoid compounds also function as anti-inflammatories and can prevent stiffness and pain (Mangla et al., 2010; Sumoza & Rahayu, 2014). Alkaloid compounds are known to aid in wound healing by acting as antibacterial agents against *Staphylococcus aureus*. Saponins and tannin compounds also contribute to the healing process of burns by aiding in the closure of damaged blood vessels and pores of the skin, respectively, which prevents bleeding and exudates. Tannins have antibacterial properties that can kill *Staphylococcus aureus* and *Klebsiella pneumonia* bacteria, which are commonly found in wounds. (Deny & Giri, 2021).

Topical preparations are often used in the treatment of burns because they can penetrate hardened tissue that oral or parenteral medications cannot. This is due to their ability to be absorbed directly into the affected area (Risma et al., 2013). Cream is a semisolid emulsion intended for external use (Kemenkes RI, 2020). Gel is a clear, translucent semi-solid preparation containing active substances for external use (Elmitra, 2017). The penetration of the drug into the skin for effective results is influenced by the dosage form. Different dosage forms have distinct mechanisms of action and can impact the skin penetration of the medication (Gennari et al., 2019; Lien et al., 2020). This study aimed to compare the effectiveness of cream and gel dosage forms and determine the optimal concentration for treating burns. Burn treatment is one using a cream with the active ingredient silver sulfadiazine, but the use of the cream inhibits the role of fibroblasts in wound closure and causes leukopenia during the first week after the injury (Samirana et al., 2020), it is expected that there are natural alternative treatments to minimize the occurrence of side effects of synthetic ingredients drugs in the treatment of burns.

According to the explanation provided, black turmeric rhizomes are believed to have healing properties for burns. However, there has been no research conducted on the use of black turmeric rhizomes specifically for burns. This lack of research has piqued the interest of researchers who aim to investigate the potential benefits of black turmeric rhizomes in the form of gel or cream preparations for burn healing. Dosage forms of gels and creams are preferred by researchers due to their ability to spread well on the skin, provide a cooling effect, and ensure good drug release. In this study, researchers formulated gel and cream preparations using three concentrations of black turmeric extract. The preparations were then tested on male white rats to evaluate their effectiveness in healing burns.

## **METHOD**

Black turmeric rhizomes are taken from Manikliyu Village, Kintamani, Bangli Regency, Bali Province. The sample was identified at the Indonesian Institute of Sciences, Eka Karya Bali Botanical Garden with registration number B-308/III/KS.01.03/1/2021. The tools used are *rotary evaporator* (BUCHI), UV-Vis Spectrophotometer (UV-1800 Shimadzu double beam), filter paper (Whatman), thermometer (Gea Medical), beaker glass (Pyrex), test tube, measuring cup (Pyrex), particle size analyzer (PSA Horiba ZS-100), pH-meter (ditech pH 600), analytical balance (Shimadzu AUW220D), chromameter (Brookfield).

### **1. Extraction of black turmeric rhizome**

The Rhizome Black Turmeric is first cleaned and then sliced into small parts with a thickness of approximately 3mm. It is then dried in an oven at 50°C. Once dried, the sample is mashed and extracted using methanol as a solvent through maceration, which is repeated three times. The filtrate is collected and concentrated using a rotary evaporator to obtain a viscous extract.

## 2. Preparation of black turmeric extract cream and gel

The process for formulating cream preparations involves heating the oil phase components, which include stearic acid, cetyl alcohol, dimethicone, propyl paraben, and methyl paraben, as well as the water phase components, which consist of TEA, propylene glycol, glycerin, and distilled water, to 70°C while continuously stirring until homogeneity is achieved. Then, the water phase is added to the oil phase using a water bath, and stirring continues until homogeneity is attained. The cream base is transferred onto a heated mortar (Mortar I) until a cream mass is achieved. Stirring persists until the mortar's temperature decreases. Meanwhile, black turmeric rhizome extract is crushed on a separate mortar (Mortar II). Aquadest is added to achieve the desired consistency, and the cream base is introduced into Mortar II. It is crushed until homogeneity is achieved. Finally, the preparation is transferred into cream pots for storage.

To fabricate a gel containing black turmeric extract, propyl paraben and methyl paraben are dissolved in distilled water in a glass beaker (mixture 1). In a separate glass beaker, black turmeric extract (for formulations incorporating this extract) is mixed with propylene glycol until homogeneity is achieved (mixture 2). Carbopol is dispersed in distilled water in a mortar and stirred until homogeneous. Triethanolamine is added, followed by glycerin, and stirred until a gel mass forms. Mixture 1 is then incorporated and stirred, followed by the addition of mixture 2. The remaining distilled water is added, and stirring continues until homogeneity is achieved. The resulting preparation is transferred into gel pots for storage.

## 3. Test of burn healing activity

The healing activity of burns was tested on male white rats (*Rattus norvegicus*) aged 2-3 months and weighing 150-200 grams. The study was approved by the Animal Ethics Committee of the Faculty of Veterinary Medicine, Udayana University (Approval Number: B/263/UN14.2.9/PT.01.04/2022). Eight groups, each consisting of five white rats, were used in the study. The study involved eight treatment groups, each receiving a different topical application: treatment 1 (cream base), treatment 2 (gel base), treatment 3 (2% black turmeric extract cream), treatment 4 (4% black turmeric extract cream), treatment 5 (8% black turmeric extract cream), treatment 6 (2% black turmeric extract gel), treatment 7 (4% black turmeric extract gel), and treatment 8 (8% black turmeric extract gel). The day before treatment, the rats' back fur was shaved. Prior to treatment, the rats were locally anesthetized with lidocaine injections. Burns were then induced using a 2cm diameter metal plate heated for approximately 3 minutes and applied to the rat's back for 7 seconds. The burns were treated twice daily. The diameter of the burn was observed for 14 days using the Morton method.

## RESULTS AND DISCUSSION

The study utilized black turmeric (*Curcuma caesia* Roxb.) sourced from the *Zingiberaceae* tribe. Black turmeric is a traditional medicinal plant that has been empirically used to treat burns (Hidayat, G.A, Hidayat et al., 2016). The obtained black turmeric is processed into simplicia powder. In the tests conducted, a greenish-brown simplicia powder with a characteristic smell of black turmeric was produced. The resulting black turmeric rhizome powder simplicia is then extracted using maceration method with the aim of separating the components of the natural active substance from the insoluble residue (Najib, 2018), (JUNAIDI, 2019). The benefits of the maceration extraction method include simplicity, the absence of a requirement for specialized equipment, and the avoidance of high temperatures during the extraction process. This prevents potential damage to compounds that could occur with elevated temperatures (Badaring et al., 2020; Debiasi et al., 2021). Because methanol is readily available and has the capacity to dissolve both polar and non-polar molecules, it was selected as the extraction solvent to facilitate the extraction of metabolites from the samples. Methanol has

several advantages when used as a solvent in maceration, including its adaptability, high extraction yields, and favorable physical characteristics (Kusnadi & Purgiyanti, 2021; Muaja et al., 2017; Osmić et al., 2019). The filtrate collected from maceration was evaporated using a rotary evaporator at 40°C, followed by further evaporation using a water bath at a maintained temperature to obtain a thick extract. The resulting thick black turmeric extract weighed 18 g and had a blackish-brown color with a distinctive odor of black turmeric. The extract was obtained from 250 g of powdered simplisia that was macerated with 2.5 L of solvent, resulting in a percentage yield of 7.2%. According to Table 1, the phytochemical screening test results indicate that the black turmeric extract tested positive for alkaloids, flavonoids, and tannins.

**Table 1**  
**Results of Phytochemical Screening Examination**

Secondary metabolite compounds	Test reagent	Black turmeric extract test results	Information
Alkaloids	Dragendrof	Orange/red-brown deposits form	Alkaloid assay with dragendrof + compounds (Positive)
Flavonoids	Mg plate + concentrated HCl + Amyl alcohol	The formation of an orange top layer	Flavonoid Test with NaOH+ compounds (Positive)
Saponins	Aquadest + Whisk 1 min	Absence of foam	Saponin Compound Test (Negative)
Tannins	FeCl 5%	There is a change in color to blackish green.	Tannin + Compound Test (Positive)

Phytochemical screening tests were conducted on the black turmeric extract to determine the class of compounds that are effective in treating burns. The tests included alkaloid compounds, flavonoids, tannins, and saponins. Based on the conducted research, it was found that black turmeric extract contains alkaloids, flavonoids, and tannins, which is consistent with previous studies (Devi & Mazumder, 2016; Hait et al., 2019; Pakkirisamy et al., 2014). However, the material that was extracted is negative and contains no saponins. This result is consistent with the research conducted by Jose and Thomas (2014) which found that when black turmeric rhizome was extracted using methanol, it tested positive for flavonoids, tannins, and alkaloids but negative for saponins.

The cream preparation of black turmeric rhizome extract involves four formulas: F1 (without extract), F2 (with 2% extract concentration), F3 (with 4% extract concentration), and F4 (with 8% extract concentration). Creams have been chosen due to their usefulness, affordability, simplicity of application, lack of stickiness, and ease of water cleansing. Because of their oil and water phases, they also stick to the skin for extended periods of time (Erwiyani et al., 2020; Stan et al., 2021; Suena et al., 2022). The cream's base is formed by combining stearic acid, which serves as an emulsifier, with triethanolamine (Saryanti et al., 2019; Sheskey et al., 2020), then cetyl alcohol which functions as a stiffening agent and weak emulgator (NUNIK KURNIASIH, 2016; Sheskey et al., 2020). The next ingredient, glycerin and propylene glycol, serves as a moisturizer, cosolvent, and humectant in addition to aiding in the penetration of active ingredients (Joko Santoso, Rina Herowati, 2018; Sheskey et al., 2020). The cream preparation contains dimethicone, which acts as an antifoaming agent to prevent foam formation. Additionally, propyl paraben and methyl paraben are included as antimicrobials to prevent fungal growth during use and storage (Loeffler et al., 2020; Sheskey et al., 2020).

The gel preparation of black turmeric rhizome extract is made using four formulas: F1 (without extract), F2 (with 2% extract concentration), F3 (with 4% extract concentration), and F4 (with 8% extract concentration). Gel preparations are a recommended option because they spread uniformly on the skin, have a cooling effect through delayed evaporation, do not impede hair growth, and are easy to remove with water. Gels are less greasy on the skin and simpler to remove. Their formulation

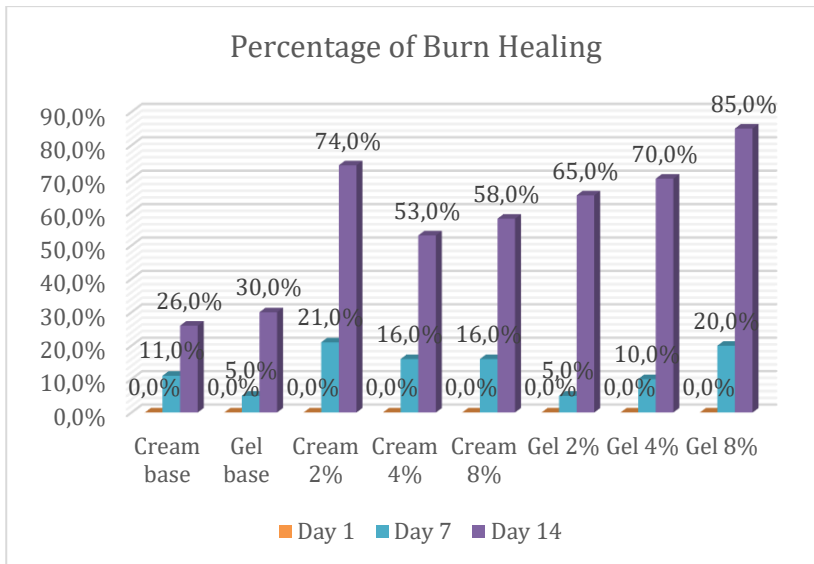
provides better application properties and stability than creams and ointments, making them a widely used topical agent. (Anggowarsito, 2014; Elmitra, 2017; Patil et al., 2019).

The materials used in this study to make gel preparations were Carbopol, triethanolamine, glycerine, propylene glycol, methylparaben, and propylparaben. Carbopol was selected as the base due to its ability to produce a transparent and clear base with a superior texture compared to Sodium CMC and Sodium alginate. Additionally, Carbopol has several advantages over other gelling agents (Kusuma et al., 2018; Safitri et al., 2021). Triethanolamine is added to Carbopol as an alkaline agent to raise its pH since it is too acidic to allow it to gel. When Carbopol raises the pH to almost neutral, gel consistency will form (Sheskey et al., 2020). Propylene glycol is utilized as a humectant to prevent water loss from the gel. To maintain the physical properties and stability of the gel preparation during storage, glycerine or water can be added to increase the stability of propylene glycol. Methylparaben and propylparaben are used as preservatives in this formula (Sheskey et al., 2020).

The efficacy of black turmeric rhizome extract (*Curcuma caesia* Roxb.) gel and cream formulations against healing burns in white rats was tested pharmacologically. The pharmacological studies were performed on 150-200-gram white rats. White rats were chosen because their bodies are larger than mice's, more manageable, and resemble humans anatomically (Otto et al., 2015; Reczyńska et al., 2018; Vdoviaková et al., 2016). For this research, 40 rats were employed, with 5 mice each group. Test animals had a seven-day period of environmental adaptation prior to treatment. On the rats' fur, shaving was done the day before the treatment. The following step involves administering a lidocaine injection locally to reduce discomfort and fast cover the sedated region prior to inducing burns. (Zhang & Kitts, 2021). The rats are then induced using a 2 cm-diameter metal plate that has been heated using a Bunsen fire for  $\pm 3$  minutes before being affixed to the rat's rear skin for 7 seconds, or until a grade II A burn forms. Rats with induced skin received treatment with creams and gels based on their groupings. The study's characteristics included the diameter of the burns, which were measured using a caliper on the first, seventh, and fourteenth days for each treatment group. Tables 2 and 3 display the average burn diameter test findings for white rats. Figure 2 shows the outcome of variations in the average value of the white rat's backburn's diameter.

**Table 2**  
**The Average Value of the Diameter of the Burn**

Group	Day 1 (cm)	Day 7 (cm)	Day 14 (cm)
Group 1 treatment	1.9 $\pm$ 0.12	1.7 $\pm$ 0.19	1.4 $\pm$ 0.15
Group 2 treatment	1.9 $\pm$ 0.05	1.5 $\pm$ 0.34	0.6 $\pm$ 0.46
Group 3 treatment	1.9 $\pm$ 0.05	1.6 $\pm$ 0.16	0.9 $\pm$ 0.51
Group 4 treatment	1.9 $\pm$ 0.05	1.6 $\pm$ 0.14.	0.6 $\pm$ 0.54
Group 5 treatment	1.9 $\pm$ 0.04	1.9 $\pm$ 0.07	1.4 $\pm$ 0.13
Group 6 treatment	2.0 $\pm$ 0.04	1.8 $\pm$ 0.05	0.6 $\pm$ 0.60
Group 7 treatment	2.0 $\pm$ 0.00	1.7 $\pm$ 0.08	0.6 $\pm$ 0.60
Group 8 treatment	2.0 $\pm$ 0.08	1.5 $\pm$ 0.22	0.3 $\pm$ 0.48



**Figure 1. Burn Healing Percentage**

Burns heal by means of an inflammatory process that starts with permeability of the cell membrane, which causes redness, swelling, and occasionally the appearance of bullae. The somewhat reddish-brown color and swelling of the burns on the white rats seen on day 1 suggest that an inflammatory process has started on that day. (Aprilliani et al., 2021; Cahaya Mentari, 2020).

Collagen will join the burnt tissues during the subsequent step, known as proliferation in this proliferative phase, which will help the skin recover more quickly and help regain its strength. When white rat burns are noticed on day three, a scab or crust/scab layer forms, marking the beginning of the wound healing process. From day five on, the crust/scab solidifies (Aprilliani et al., 2021). The final stage, known as the maturase or remodeling phase, starts when the reepitalization process is complete and the wound activity is filled with granulation tissue (Fallo, 2019). The scab is released during the maturase phase, which also marks the appearance of new skin tissue. Scab detachment is gradually noticeable starting on day 9. The underlying tissue becomes dry, causing the edges of the incision to draw inward and induce scab separation. This shows that new skin cells are growing, which will quicken the scab's release and the wound's edge's tightening (Priamsari & Yuniawati, 2019).

Upon acquiring the findings from the burn diameter investigation conducted on white rats on days 1, 7, and 14, the subsequent phase involved executing Kruskal-Wallis statistical analyses. When dealing with non-normally distributed samples, the Kruskal-Wallis test is employed to separate more than two samples. Based on the findings of the Kruskal-Wallis test, it can be inferred that there is a significant difference in the diameter of burns across groups on day 7, with the burn diameter result having a p value of  $< 0.05$  ( $p = 0.007$ ). After comparing the diameter of the burns between the groups on day 14, a p value of  $< 0.05$  ( $p = 0.001$ ) was found. This means that there was a significant difference in the burns' diameters on day 14. A post hoc analysis employing the Mann-Whitney test was conducted following the Kruskal-Wallis statistical test in order to ascertain the significant difference. The treatment groups of cream base and gel base showed significant differences ( $p < 0.05$ ) in the Mann-Whitney test of burn diameter data on day 7. The 2% extract cream treatment group, 4% extract cream, 8% extract cream, 2% extract gel, 4% extract gel, and 8% extract gel were all substantially different from the gel-based therapy group ( $p < 0.05$ ). There were significant changes ( $p < 0.05$ ) between the 2% extract gel groups in the 2% extract cream treatment group. There was a significant difference ( $p < 0.05$ ) between the treatment groups of 8% extract cream, 2% extract gel, and 4% extract gel. The results indicate that there is a difference in the effectiveness of burn healing between

2% extract cream with 2% extract gel, 8% extract cream with 2% extract gel, and 4% extract gel, and 2% extract gel with 8% extract gel. The 2% extract gel treatment group showed significant differences with the 8% extract gel group ( $p < 0.05$ ). The cream base treatment group with the cream extract treatment group 2%, cream extract 4%, cream extract 8%, gel extract 2%, gel extract 4%, and gel extract 8%, respectively, had a significant difference ( $p < 0.05$ ) on day 14 according to the Mann-Whitney test results. Between the 2% extract cream treatment group and the 4% extract cream treatment group, as well as between the 8% extract cream, 2% extract gel, 4% extract gel, and 8% extract gel, there were significant differences ( $p < 0.05$ ) observed in the gel-based treatment group. However, there was no significant difference ( $p > 0.05$ ) between the 2% extract cream treatment group and any of these groups. There was no statistically significant difference ( $p > 0.05$ ) between the 4% extract cream group and the 8% extract cream group, 2% extract gel, 4% extract gel, and 8% extract gel. There were no notable differences between the 8% extract cream group and the 2%, 4%, and 8% extract gel groups ( $p > 0.05$ ). There were no significant differences between the 2% extract gel group and the 4% extract gel treatment group, the 8% extract gel ( $p > 0.05$ ), or the 4% extract group and the 8% extract gel treatment group ( $p > 0.05$ ). On day 14, there was no discernible difference in the rate of burn healing in the group of white rats given black turmeric extract in gel and cream preparations.

The percentage of burn healing for each group on day 14 varied, according to the study's findings: P1 26%, P2 30%, P3 74%, P4 53%, P5 58%, P6 65%, P7 70%, and P8 85%. This demonstrated which treatment groups were most successful in healing subsequent burns: P8 (concentration of gel extract: 8%), P3 (concentration of cream extract: 2%), P7 (concentration of gel extract: 4%), P6 (concentration of gel extract: 2%), P5 (concentration of cream extract: 8%), P4 (concentration of cream extract: 4%), P2 (gel without extract addition), and P1 (cream without extract addition). A gel with an extract concentration of 8% and a cream with an extract concentration of 4% are the most effective preparations, respectively, based on the percentage of burn healing in white rats. Both gel and cream therapies, depending on their dose forms, are useful in healing burns; however, gel preparations work best. This implies that cream and gel dosage forms have an impact on how quickly burns in white rats heal. Gels typically have a longer contact time on the skin than creams, which allows the active components to function more effectively on skin burns. This may account for the gel's superior efficacy in healing burns compared to the cream in this study. As a first-line treatment for skin burns, gels also have cooling properties that reduce discomfort and inflammation (Kulawik-Pióro & Miastkowska, 2021; Miastkowska et al., 2020).

Black turmeric extract's secondary metabolites, which include flavonoids, tannins, and alkaloids, are responsible for the healing of burns in white rats (Ibrahim et al., 2023). Alkaloids have antibacterial properties against *Staphylococcus aureus*, which aid in the healing of burn injuries. In addition to being antioxidants and capable of absorbing free radicals, flavonoids are also anti-inflammatory and anti-carcinogenic. They also have anti-inflammatory properties that help to reduce pain and stiffness (Mangla et al., 2010; Sumoza & Rahayu, 2014). Tannin molecules are also crucial to the healing process after burns. Tannins reduce the size of skin pores, inhibit small amounts of bleeding and exudates, and stop wound bleeding. Tannins also have antibacterial properties; they eradicate germs like *Klebsiella pneumonia* and *Staphylococcus aureus*, which are frequently found in wounds (Deny & Giri, 2021).

## CONCLUSIONS AND SUGGESTIONS

According to this study, P8 (8% extract concentration gel) and P3 (2% extract concentration cream) were the two preparations that healed burns the fastest, with 85% and 74%, respectively. This indicates that the topical dosage form influences the rate of burn healing in male white rats (*Rattus norvegicus*). Burns can be healed using either of the topical dosage forms (cream or gel), but the gel

preparation works best. Further research needs to be done on the formulation and stability testing of black currant extract cream to obtain a preparation that has qualified and durable physical qualities of the cream.

### **Acknowledgment**

The authors would like to thank LPPM Universitas Mahasaraswati Denpasar in accordance with the Basic Research Contract of Unmas Denpasar Number: K.100/B.01.01/LPPM UNMAS/V/2022, which has financed this research.

### **Conflict of Interest Statement**

The authors declare there is no conflict of interest.

### **REFERENCES**

- Anggowarsito, J. L. (2014). Luka Bakar Sudut Pandang Dermatologi. *Jurnal Widya Medika*, 2(2), 115–120.
- Aprilliani, A., Fhatonah, N., & Ashari, N. A. (2021). Uji Efektivitas Antiinflamasi Ekstrak Etanol 70% Daun Dewa (*Gynur pseudochina* (L.) DC.) pada Luka Bakar Tikus Putih Jantan Galur Wistar. *Jurnal Farmagazine*, 8(2), 52. <https://doi.org/10.47653/farm.v8i2.564>
- Badaring, D. R., Sari, S. P. M., Nurhabiba, S., Wulan, W., & Lembang, S. A. R. (2020). Uji Ekstrak Daun Maja (*Aegle marmelos* L.) terhadap Pertumbuhan Bakteri *Escherichia coli* dan *Staphylococcus aureus*. *Indonesian Journal of Fundamental Sciences*, 6(1), 16. <https://doi.org/10.26858/ijfs.v6i1.13941>
- Baghel, S., Baghel, R., Sharma, K., & Sikarwar, I. (2013). Pharmacological activities of *Curcuma caesia*. *International Journal of Green Pharmacy*, 7(1), 1. <https://doi.org/10.4103/0973-8258.111590>
- Cahaya Mentari. (2020). FORMULASI DAN UJI EFEKTIVITAS SEDIAAN KRIM ANTIINFLAMASI KOMBINASI MINYAK IKAN SIDAT (*Anguilla* sp.) dan GAMAT (*Stichopus* sp.) PADA LUKA BAKAR TIPE II. *PROGRAM STUDI FARMASI FAKULTAS FARMASI UNIVERSITAS HASANUDDIN MAKASSAR*.
- Debiasi, B. W., Rodrigues, P. G. R. S., Torres, M. P. R., Bonacorsi, C., Andrighetti, C. R., Ribeiro, E. B., & Valladão, D. M. S. (2021). Comparison between maceration and ultrasound-assisted extraction of white bracts with flowers of *Bougainvillea spectabilis* Willd. *Scientific Electronic Archives*, 14(2), 47. <https://doi.org/10.36560/14220211297>
- Deny, I. M., & Giri, S. (2021). *Peran Metabolit Sekunder Tumbuhan dalam Pembentukan Kolagen pada Kulit Tikus yang Mengalami Luka Bakar Role of Plant Secondary Metabolites in Collagen Formation of Burned Rats Skin*. 1(1), 23–29.
- Devi, H., & Mazumder, P. (2016). Methanolic Extract of *Curcuma caesia* Roxb. prevents the toxicity caused by Cyclophosphamide to bone marrow cells, liver and kidney of mice. *Pharmacognosy Research*, 8(1), 43. <https://doi.org/10.4103/0974-8490.171106>
- Elmitra. (2017). Dasar-dasar farmasetika dan sediaan semi solid. In H. Rahmadhani & H. A.. Susanto (Ed.), *CV BUDI UTAMA* (1st ed.).

- Erwiyani, A. R., Haswan, D., Agasi, A., & Karminingtyas, S. R. (2020). Pengaruh Sediaan Gel dan Krim Ekstrak Etanol Daun Kelor (*Moringa Oleifera* Lamk.) terhadap Penurunan Luas Luka Bakar pada Tikus. *Indonesian Journal of Pharmacy and Natural Product*, 3(2), 41–52. <https://doi.org/10.35473/ijpnp.v3i2.666>
- Fallo, E. B. (2019). FORMULASI DAN UJI EFEKTIVITAS KRIM KOMBINASI EKSTRAK KUNYIT DAN LIDAH BUAYA TERHADAP PENYEMBUHAN LUKA BAKAR. *Skripsi. PROGRAM STUDI SARJANA FARMASI%0AUNIVERSITAS CITRA BANGSA%0AKUPANG*
- Gennari, C. G. M., Selmin, F., Minghetti, P., & Cilurzo, F. (2019). Medicated Foams and Film Forming Dosage Forms as Tools to Improve the Thermodynamic Activity of Drugs to be Administered Through the Skin. *Current Drug Delivery*, 16(5), 461–471. <https://doi.org/10.2174/1567201816666190118124439>
- Hait, M., Bhardwaj, A. K., Kashyap, N. K., & Vaishnav, M. M. (2019). Physicochemical and phytochemical evaluation on non-areal part of *Curcuma caesia*. *The Pharma Innovation Journal*, 8(5), 514–517.
- Hidayat, G.A, Hidayat, G. ., Widayat, W., & Rusli, R. (2016, November). Isolasi Jamur Endofit Rimpang Kunyit Hitam (*Curcuma caesia* Roxb.). *Proceeding of the 4th Mulawarman Pharmaceuticals Conferences*. <https://doi.org/10.25026/mpc.v4i1.173>
- Ibrahim, N. N. A., Kamal, N., Mediani, A., Sajak, A. A. B., Lee, S. Y., Shaari, K., & Rahman, H. A. (2023). <sup>1</sup>H NMR-Based Metabolomics Approach Revealing Metabolite Variation of Black Turmeric (*Curcuma caesia*) Extracts and Correlation with Its Antioxidant and  $\alpha$ -Glucosidase Inhibitory Activities. *Food Technology and Biotechnology*, 61(1), 104–117. <https://doi.org/10.17113/ftb.61.01.23.7711>
- Irham Rahman Hakim, Fetri Lestari, S. E. P. (2021). Kajian Pustaka Tanaman yang Berpotensi dalam Penyembuhan Luka Bakar. *Prosiding Farmasi*, 7(1), 14–20. <https://doi.org/http://dx.doi.org/10.29313/.v7i1.25982>
- Jibalathuull, F. S., Fadraersada, J., & Rijai, L. (2017). Aktivitas Tabir Surya Ekstrak Rimpang Kunyit Hitam (*Curcuma caesia*) secara In-Vitro. *Proceeding of the 5th Mulawarman Pharmaceuticals Conferences*, 129–134. <https://doi.org/10.25026/mpc.v5i1.228>
- Joko Santoso, Rina Herowati, M. M. (2018). OPTIMASI FORMULA KRIM EKSTRAK POLIHERBAL SEBAGAI ANTIBAKTERI DENGAN KOMBINASI GLISERIN, SORBITOL DAN PROPILENGLIKOL SEBAGAI HUMEKTAN. *Parapemikir Jurnal Ilmiah Farmasi*, 7(2), 1–5.
- JUNAIDI, L. (2019). *Teknologi Ekstraksi Bahan Aktif Alami*. Lukman Junaidi.
- Kemenkes RI. (2020). Farmakope Indonesia Edisi VI. *Departemen Kesehatan Republik Indonesia*.
- Kulawik-Pióro, A., & Miastkowska, M. (2021). Polymeric Gels and Their Application in the Treatment of Psoriasis Vulgaris: A Review. *International Journal of Molecular Sciences*, 22(10), 5124. <https://doi.org/10.3390/ijms22105124>
- Kusnadi, & Purgiyanti. (2021). Quantification of polyphenol, antioxidant, and antibacterial from red and purple roselle calyces using maceration extraction under different solvent conditions. *Journal of Physics: Conference Series*, 1918(5), 052007. <https://doi.org/10.1088/1742-6596/1918/5/052007>

- Kusuma, A. F., Abdassah, M., & Valas, B. E. (2018). Formulation and Evaluation of Anti Acne Gel Containing Citrus aurantifolia Fruit Juice using Carbopol as Gelling Agent. *International Journal of Applied Pharmaceutics*, 10(4), 147. <https://doi.org/10.22159/ijap.2018v10i4.26788>
- Lien, Y. V., R. M., Chinnappan, S., Janakiraman, A. K., & Fang, T. L. (2020). Topical Dosage Form & Delivery System for Pigmentation Control: A Review. *International Journal of Research in Pharmaceutical Sciences*, 11(SPL4), 1341–1349. <https://doi.org/10.26452/ijrps.v11iSPL4.4303>
- Loeffler, M., Schwab, V., Terjung, N., Weiss, J., & Julian McClements, D. (2020). Influence of protein type on the antimicrobial activity of LaE alone or in combination with methylparaben. *Foods*, 9(3). <https://doi.org/10.3390/foods9030270>
- Mangla, M., Shuaib, M., Jain, J., & Kashyap, M. (2010). In-vitro Evaluation of antioxidant activity of Curcuma caesia Roxb. *International Journal of Pharmaceutical Sciences and Research*, 1(9), 98–102.
- Miastkowska, M., Kulawik-Pióro, A., & Szczurek, M. (2020). Nanoemulsion Gel Formulation Optimization for Burn Wounds: Analysis of Rheological and Sensory Properties. *Processes*, 8(11), 1416. <https://doi.org/10.3390/pr8111416>
- Muaja, M. G. D., Runtuwene, M. R. J., & Kamu, V. S. (2017). Aktivitas Antioksidan Ekstrak Metanol dari Daun Soyogik (Saurauia Bracteosa DC.). *Jurnal Ilmiah Sains*, 17(1), 68–72. <https://doi.org/10.35799/jis.17.1.2017.15614>
- Najib, A. (2018). *Ekstraksi Senyawa Bahan Alam* (N. F. Subekti & D. Novidiantoko (eds.); 1st ed.). Deepublish Publisher.
- NUNIK KURNIASIH. (2016). FORMULASI SEDIAAN KRIM TIPE M/A EKSTRAK BIJI KEDELAI ( Glycine max L): UJI STABILITAS FISIK DAN EFEK PADA KULIT. *FAKULTAS FARMASI UNIVERSITAS MUHAMMADIYAH SURAKARTA*.
- Osmić, S., Begić, S., Mičić, V., Petrović, Z., & Avdić, G. (2019). Effect of Solvent and Extraction Conditions on Antioxidative Activity of Sage (Salvia officinalis L.) Extracts Obtained by Maceration. *Technologica Acta*, 11(2), 1–8. <https://doi.org/10.5281/zenodo.2563049>
- Otto, G. M., Franklin, C. L., & Clifford, C. B. (2015). Biology and Diseases of Rats. In *Laboratory Animal Medicine* (Vol. 212, Issue 1, pp. 151–207). Elsevier. <https://doi.org/10.1016/B978-0-12-409527-4.00004-3>
- Pakkirisamy, M., Kalakandan, S. K., & Ravichandran, K. (2014). Phytochemical screening, GC-MS, FT-IR analysis of methanolic extract of Curcuma caesia roxb (black turmeric). *Pharmacognosy Journal*, 9(6), 952–956. <https://doi.org/10.5530/pj.2017.6.149>
- Patil, P. B., Datir, S. K., & Saudagar, R. B. (2019). A Review on Topical Gels as Drug Delivery System. *Journal of Drug Delivery and Therapeutics*, 9(3-s), 989–994.
- Priamsari, M. R., & Yuniawati, N. A. (2019). Skrining Fitokimia dan Aktivitas Penyembuhan Luka Bakar Ekstrak Etanolik Morinda Citrifolia L. pada Kulit Kelinci (Oryctolagus Cuniculus). *Jurnal Farmasi (Journal of Pharmacy)*, 8(1, Oktober), 22–28. <https://doi.org/10.37013/jf.v1i8.76>

- Reczyńska, K., Tharkar, P., Kim, S. Y., Wang, Y., Pamuła, E., Chan, H.-K., & Chrzanowski, W. (2018). Animal models of smoke inhalation injury and related acute and chronic lung diseases. *Advanced Drug Delivery Reviews*, *123*, 107–134. <https://doi.org/10.1016/j.addr.2017.10.005>
- Rismana, E., Rosidah, I., Y, P., Bunga, O., & Y, E. (2013). *EFEKTIVITAS KHASIAT PENGOBATAN LUKA BAKAR SEDIAAN GEL MENGANDUNG FRAKSI EKSTRAK PEGAGAN BERDASARKAN ANALISIS HIDROKSIPROLIN DAN HISTOPATOLOGI PADA KULIT KELINCI*. E-Journal Badan Penelitian Dan Pengembangan Kesehatan/ Nasional Institute of Research and Development.
- Safitri, F. I., Nawangsari, D., & Febrina, D. (2021). Overview: Application of Carbopol 940 in Gel. *Proceedings of the International Conference on Health and Medical Sciences (AHMS 2020)*, *34*(Ahms 2020), 80–84. <https://doi.org/10.2991/ahsr.k.210127.018>
- Samirana, P. O., Satriani, N. W., Harfa, P. R., Dewi, S. P. P., & Arisanti, C. I. S. (2020). Formulasi Sediaan Krim Anti Luka Bakar Dari Ekstrak Air Daging Daun Aloe Vera. *Jurnal Kimia*, *August*, *37*. <https://doi.org/10.24843/jchem.2020.v14.i01.p07>
- Saryanti, D., Setiawan, I., & Safitri, R. A. (2019). Optimasi Asam Stearat dan TEA pada Formula Sediaan Krim Ekstrak Kulit Pisang Kepok (*Musa paradisiaca* L.). *Jurnal Riset Kefarmasian Indonesia*, *1*(3), 225–237. <https://doi.org/10.33759/jrki.v1i3.44>
- Sheskey, P. J., Hancock, B. C., Moss, G. P., & Goldfarb, D. J. (2020). *Handbook of Pharmaceutical Excipients* (P. J. Sheskey, B. C. Hancock, G. P. Moss, & D. J. Goldfarb (eds.); 9th ed.). Pharmaceutical Press and American Pharmacist Association.
- Stan, D., Tanase, C., Avram, M., Apetrei, R., Mincu, N., Mateescu, A. L., & Stan, D. (2021). Wound healing applications of creams and “smart” hydrogels. *Experimental Dermatology*, *30*(9), 1218–1232. <https://doi.org/10.1111/exd.14396>
- Suena, N. M. D. S., Ariani, N. L. W. M., & Antari, N. P. U. (2022). Physical Evaluation and Hedonic Test of Sandalwood Oil (*Santalum album* L.) Cream as an Anti-Inflammatory. *Jurnal Ilmiah Medicamento*, *8*(1), 22–30. <https://doi.org/10.36733/medicamento.v8i1.3425>
- Sumoza, N. S., & Rahayu, R. (2014). *Pengaruh Gambir (Uncaria gambir R.) Terhadap Penyembuhan Luka Bakar Pada Mencit Putih (Mus musculus L.) Jantan The Effect of Gambier (Uncaria gambir R.) on Burned Skin of Male White Mice ((Mus musculus L.)*. *3*(4), 283–288.
- Thomas, Td., & Jose, S. (2014). Comparative phytochemical and anti-bacterial studies of two indigenous medicinal plants *Curcuma caesia* Roxb. and *Curcuma aeruginosa* Roxb. *International Journal of Green Pharmacy*, *8*(1), 65. <https://doi.org/10.4103/0973-8258.126828>
- Vdoviaková, K., Petrovová, E., Maloveská, M., Krešáková, L., Teleky, J., Elias, M. Z. J., & Petrášová, D. (2016). Surgical anatomy of the gastrointestinal tract and its vasculature in the laboratory rat. *Gastroenterology Research and Practice*, *2016*. <https://doi.org/10.1155/2016/2632368>
- Zhang, H. A., & Kitts, D. D. (2021). Turmeric and its Bioactive Constituents Trigger Cell Signaling Mechanisms that Protect Against Diabetes and Cardiovascular Diseases. *Molecular and Cellular Biochemistry*, *476*(10), 3785–3814. <https://doi.org/10.1007/s11010-021-04201-6>